

Success Rate of Common Bile Duct Stones Extraction on First ERCP Attempt

Abdul Samad¹, Syed Zea ul Islam Farrukh¹, Syed Afzal Haqqi¹, Arif Rasheed Siddiqui¹, Saad Khalid Niaz¹, Muhammad Zahid Qadri²

ABSTRACT

Objective: To determine the success rate of common bile duct stones extraction on first endoscopic retrograde cholangiopancreatography (ERCP) attempt among patients with suspected choledocholithiasis.

Methods: This retrospective study was performed from January 2012 till December 2015. All patients diagnosed with choledocholithiasis on the basis of sonographic or other radiological evidence of Common Bile Duct stones or patients who had cholestatic liver functions on the background of gallstones were included. Data were retrieved from the endoscopic database.

Results: Out of 612 patients with suspected choledocholithiasis, stones were found on ERCP in 592 patients (96.75%). During the first attempt at ERCP, 480 patients out of 592 had complete duct clearance (81.08%). The percentage of stones cleared via balloon was 434 (90.42%) and via basket was 46 (9.58%). The plastic stent was placed in remaining 112 patients (18.30%) that were kept on the list for follow up ERCP. A total of 44 patients out of 592 underwent sphincteroplasty (7.4%), in which 32 patients had complete duct clearance (72.72%), whereas 12 patients have stent placement (27.27%). Complete duct clearance on first ERCP attempt was found significantly associated with age (p-value 0.011) and stone diameter (p-value <0.001).

Conclusion: In our experience, at first ERCP attempt, the stone extraction rate is around 81.08%. This relates to the expertise in doing ERCP. The size and shape of stone and size of Bile duct are the predominant reason behind the failure of stone extraction on first ERCP attempt.

Key words: Common bile duct, endoscopic retrograde cholangiopancreatography (ERCP).

How to cite this article: Samad A, Farrukh SZ, Haqqi SA, Siddiqui AR, Niaz SK, Qadri MZ. Success rate of common bile duct stones extraction on first ERCP attempt. J Dow Uni Health Sci 2018; 12(3): 81-85.

INTRODUCTION

Endoscopic retrograde cholangiopancreatography (ERCP) is a widely used endoscopic procedure.¹ Though in past ERCP was only used as a diagnostic modality but now various

biliopancreatic pathologies are now treated through ERCP.^{2,3} In particular, for choledocholithiasis, various studies have reported ERCP as a safe, fast and effective modality for the extraction of common bile duct stone.^{4,6} Moreover, it is stated that endoscopic sphincterotomy followed by large balloon dilation represents the onset of a new era in large bile duct stone extraction and the management of impaction.⁷

Several studies have reported ERCP as an effective tool for the treatment of biliopancreatic pathologies.^{2,4} However, numerous complications have been linked with ERCP and the role of endoscopists is reported to be very vital in the success of the ERCP procedure. To

1. Department of Gastroenterologist, Patel Hospital Karachi, Pakistan.

2. Department of Gastroenterologist, Civil Hospital Karachi, Pakistan.

Correspondence:

Dr. Abdul Samad

Department of Gastroenterologist, Patel Hospital Karachi, Pakistan.

Email: samaddhedhi@gmail.com

cope up the complication associated with ERCP, it is stated that a competent and experienced skillful endoscopists with high success rate should perform ERCP. Studies also reported that endoscopists should perform at least 200 ERCP as a trainee before independently performed ERCP procedure.^{8,9}

ERCP with biliary sphincterotomy is the usual method to extract common bile duct stones. However, after sphincterotomy and by means of balloon and dormia basket, not all stones can be extracted during the first ERCP session. We present our experience regarding endoscopic extraction at first attempt.

METHODS

A retrospective study was conducted at our institute from January 2012 till December 2015. The requirement of informed consent was waived as data were collected from the endoscopic database. All patients diagnosed with choledocholithiasis on the basis of evidence of CBD stones through abdominal ultrasound and/or computed tomography or Magnetic resonance cholangiopancreatography or patients who had cholestatic liver functions on the background of gallstones were included. While all patients having positive history of pancreatolithiasis, pancreas divisum, or gastrointestinal hemorrhage and open surgery were excluded. Two experienced endoscopists with more than 10 years of experience in ERCP performed the procedure. The procedure was performed under sedation anesthesia. The presence of CBD stone was confirmed through wire-guided assisted cannulation, cholangiography. The extraction basket or balloon was used for the purpose of stone removal.

Information regarding demographic characteristics of patients like age and gender of the patients along with other variables like bilirubin level, the presence of CBD stone, stones diameter, duct clearance, Sphincterotomy, balloon, stent, Sphicteroplasty, basket, stricture, the outcome of ERCP were collected. Statistical Package for Social Sciences (SPSS)

version 24 was used for the purpose of statistical analysis. Mean and the standard deviation was calculated for quantitative variables like age, bilirubin level, and stones diameter whereas frequency and percentages were calculated for categorical variables like gender, bilirubin level, the presence of CBD stone, duct clearance, Sphincterotomy, balloon, stent, Sphicteroplasty, basket, stricture, and outcome of ERCP. A comparison was done to see the association of complete duct clearance on first ERCP attempt with baseline characteristics. Chi-square test was applied. P-value <0.05 was taken as significant.

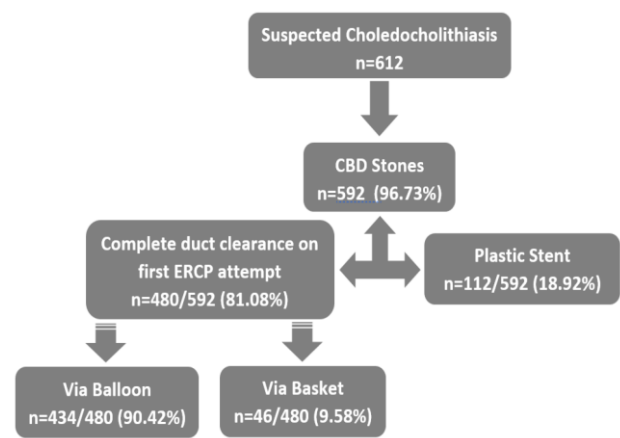


Figure 1: Flowchart of patient enrollment showing total suspected choledocholithiasis with the presence of CBD and outcome of first ERCP attempt

RESULTS

A total of 612 patients with suspected choledocholithiasis were included. The mean age of the patient was 52.86 ± 8.33 years. Majority of the patients were females (n=404, 66.01%) while 208 (33.98%) were males. Stones were found on ERCP in 592 patients (96.75%), while the remaining 20 patients (3.25%) had no stones with either normal or minimally dilated common bile duct. During the first attempt at ERCP, 480 patients out of 592 had complete duct clearance (81.08%). Amongst 480 patients with complete duct clearance on first attempt, the percentage of stones cleared via balloon was 434 (90.42%)

and via basket was 46 (9.58%). The plastic stent was placed in remaining 112 patients (18.30%) that were kept on the list for follow up ERCP. A flowchart of patient enrollment showing total suspected choledocholithiasis with the presence of CBD and outcome of first ERCP attempt is shown in figure 1. The mean size of stone extracted was 1.09 ± 0.023 cm.

A significant association of complete duct clearance on first ERCP attempt was observed with age (p-value 0.011) and stone diameter (p-value <0.001) (Table 1).

A total of 44 patients out of 592 underwent sphincteroplasty (7.4%), in which 32 patients had complete duct clearance (72.72%), whereas 12 patients have stent placement (27.27%) (Figure 2).

Table 1: Comparison of complete duct clearance on first ERCP attempt with general characteristics of the patients with CBD stones (n=592)

	Complete duct clearance on first ERCP attempt			
	Total	Yes	No	p-value
Age, years	52.88 ±15.96	52.07 ±16.08	56.35 ±15.01	0.011†
≤50	291	247 (84.9)	44 (15.1)	0.02‡
>50	301	233 (77.4)	68 (22.6)	
Gender				
Male	200	160 (80)	40 (20)	0.631‡
Female	392	320 (81.6)	72 (18.4)	
Stones Diameter, cm	1.10 ±0.44	1.02 ±0.41	1.45 ±0.40	<0.001†
≤1	306	294 (96.1)	12 (3.9)	<0.001‡
>1	281	181 (64.4)	100 (35.6)	

†Independent t-test applied, ‡Chi-square test applied, p-value <0.05 taken as significant

DISCUSSION

ERCP is a widely used endoscopic procedure.^{10,11} In particular, after its successful implication in treating various biliopancreatic pathologies, its usage is highly increased. In this current study, the experience regarding endoscopic extraction at first attempt in a tertiary care hospital of Karachi was reported. The finding of this study has reported that on

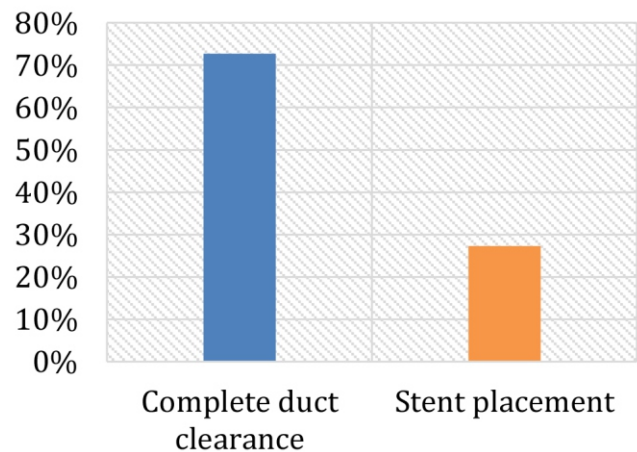


Figure 2: Outcome of patients underwent sphincteroplasty (n=44)

ERCP, stones was observed in majority of the patients with suspected choledocholithiasis. Moreover, during the first attempt at ERCP, complete duct clearance was also reported in majority of the patients. These findings are supported by several recent studies that has reported efficacy of ERCP for clearing stones in CBD.¹²⁻¹⁴

In this study, overall mean stone diameter was approximately 1 whereas mean stone diameter was significantly lower among patients in whom complete duct clearance was observed on first attempt on ERCP than that of those in which mean stone diameter was higher. This finding also supported by the various studies in which it was stated that ERCP procedure was failed among patients in whom large stone size was present.^{12,15}

In this study, a significant association of complete duct clearance on first ERCP attempt was observed with age and stone diameter. Similar to the current study findings, Zulli C et al in 2018 also reported age and stone diameter as the significant factors associated with complete duct clearance on first ERCP attempt. Moreover, in their study, author also reported that patients with younger age and higher stone diameter are also at risk of adverse effects of ERCP.¹⁶

Another study conducted in Spain reported that after endoscopic biliary sphincterotomy and by means of baskets and balloons, at first ERCP attempt, complete stone clearance was

observed in majority of the patients.¹⁷ Furthermore, they also reported failed complete stone clearance among patients with higher stone size. In their study, failed complete stone was significantly higher among females. However, in the current, no significant association of gender was observed. In addition to this, contrary to our study findings, complications were also observed in most of the cases in their study.¹⁷ The findings of this study could be observed in the light of limitation that this study failed to collect data after discharge. Previously studies were conducted in which follow-up was done on 1st, 3rd and 6th month of discharge.¹² Further large-scale prospective studies are recommended which not only determined the success rate on first ERCP attempt but the follow-up findings in these patients as well.

CONCLUSION

In our experience, at first ERCP attempt, the stone extraction rate is around 81.08%. This relates to the expertise in doing ERCP. The size and shape of stone and size of Bile duct are the predominant reason behind the failure of stone extraction on first ERCP attempt.

REFERENCES

- Jorgensen J, Kubiliun N, Law JK, Al-Haddad MA, Bingener-Casey J, Christie JA, et al. Endoscopic retrograde cholangiopancreatography (ERCP): core curriculum. *Gastrointest Endosc* 2016; 83:279-89.
- Adler DG, Lieb II JG, Cohen J, Pike IM, Park WG, Rizk MK, et al. Quality indicators for ERCP. *Am J Gastroenterol* 2015; 110: 91-101.
- Yoo KS, Lehman GA. Endoscopic management of biliary ductal stones. *Gastroenterol Clin North Am* 2010; 39: 209-27.
- Wong JC, Tang RS, Teoh AY, Sung JJ, Lau JY. Efficacy and safety of novel digital single-operator peroral cholangioscopy-guided laser lithotripsy for complicated biliary stones. *Endosco Int Open* 2017; 5:E54-E58.
- Williams E, Beckingham I, El Sayed G, Gurusamy K, Sturgess R, Webster G, Young T. Updated guideline on the management of common bile duct stones (CBDS). *Gut* 2017; 66: 765-82.
- Gupta N. Role of laparoscopic common-bile duct exploration in the management of choledocholithiasis. *World J Gastrointest Surg* 2016; 8:376-81.
- Stefanidis G, Christodoulou C, Manolakopoulos S, Chuttani R. Endoscopic extraction of large common bile duct stones: A review article. *World J Gastrointest Surg* 2012; 4:167-79.
- Faulx AL, Lightdale JR, Acosta RD, Agrawal D, Bruining DH, Chandrasekhara V, et al. Guidelines for privileging, credentialing, and proctoring to perform GI endoscopy. *Gastrointest Endosco* 2017; 85(2):273-81.
- Springer J, Enns R, Romagnuolo J, Ponich T, Barkun AN, Armstrong D. Canadian credentialing guidelines for endoscopic retrograde cholangiopancreatography. *Can J Gastroenterol* 2008; 22:547-51.
- Itoi T, Watanabe H, Gotoda T, Tsuda H, Ootaka H. Therapeutic endoscopic retrograde cholangiopancreatography using a large dilating balloon in a patient with upside-down stomach and bile duct stones (with video). *J Hepatobiliary Pancreat Sci* 2015; 22:177-9.
- Itokawa F, Itoi T, Sofuni A, Kurihara T, Tsuchiya T, Ishii K, et al. Mid-term outcome of endoscopic sphincterotomy combined with large balloon dilation. *J Gastroenterol Hepatol* 2015; 30:223-9.
- Wang X, Dai C, Jiang Z, Zhao L, Wang M, Ma L, et al. Endoscopic retrograde cholangiopancreatography versus laparoscopic exploration for common bile duct stones in post-cholecystectomy patients: a retrospective study. *Oncotarget* 2017; 8:82114-22.
- Tantau M, Mercea V, Crisan D, Tantau A, Mester G, Vesa S, et al. ERCP on a cohort of 2,986 patients with cholelithiasis: a 10-year experience of a single center. *J Gastrointest Liver Dis* 2013; 22:141-7.

14. Wang B, Guo Z, Liu Z, Wang Y, Si Y, Zhu Y, et al. Preoperative versus intraoperative endoscopic sphincterotomy in patients with gallbladder and suspected common bile duct stones: system review and meta-analysis. *Surg Endos* 2013; 27:2454–65.
15. Garg PK, Tandon RK, Ahuja V, Makharia G-K, Batra Y. Predictors of unsuccessful mechanical lithotripsy and endoscopic clearance of large bile duct stones. *Gastrointest Endosc* 2004; 59:601–5.
16. Zulli C, Grande G, Tontini GE, Labianca O, Geraci G, Sciumè C, et al. Endoscopic papillary large balloon dilation in patients with large biliary stones and periampullary diverticula: Results of a multicentric series. *Dig Liver Dis* 2018; 50:828-32.
17. García-Cano JL, González JM, Pérez AS, Morillas MA. Success rate of complete extraction of common bile duct stones at first endoscopy attempt. *Rev Esp Enferm Dig* 2002; 94:340-50.

