

CASE SERIES

## Early Total Care Versus Damage Control Orthopedics in Polytrauma

### Pediatrics Patients: A Case Series

Faris Indra Prahasta Bin Didi Indra, Mohd Anuar Ramdhan Bin Ibrahim

Faculty of Medicine and Health Sciences, University Malaysia, Sarawak, 94300 Kota Samarahan, Sarawak, Malaysia.

**Correspondence to:** Dr. Faris Indra, Email: [prahasta\\_82@yahoo.com](mailto:prahasta_82@yahoo.com), ORCID: [0000-0002-8705-3580](https://orcid.org/0000-0002-8705-3580)

#### ABSTRACT

The management of polytrauma patients had undergone tremendous evolution. We would like to share the immediate outcome of two cases of polytrauma pediatric patients managed with early total care (ETC) and damage control orthopedic (DCO) principles. We reported two polytrauma pediatric patients who were categorized as borderline case. The first patient was managed using ETC principle while the second patient was treated using DCO approach. The length of post-operative intensive care unit admission, duration of ventilation, numbers and duration of antibiotics, post-surgery sepsis, infection rate and bony union time were analyzed. From our case series, DCO principle could lead to lesser post-operative complications, shorter hospital admission duration, and antibiotic duration. The incidence of infection was less and the fractures had faster union. It is concluded that polytrauma pediatric patients categorized under borderline group managed using DCO approach has more favorable short-term outcome and should be managed by multidisciplinary teams to achieve excellent result.

**Keywords:** External Fixation, Fractures, Intensive Care Units, Multidisciplinary Team, Pediatric, Polytrauma.

This is an Open Access article distributed under the terms of the Creative Commons Attribution Non-Commercial License (<http://creativecommons.org/licenses/by-nc/4.0>) which permits unrestricted non-commercial use, distribution, and reproduction in any medium, provided the original work is properly cited.

#### INTRODUCTION

The management of polytrauma children with multiple long bone fractures is a challenge for orthopedic surgeons.<sup>1</sup> Associated long bone fractures can lead to devastating systemic complications during the early and late postoperative period, leading to acute respiratory distress syndrome, infection, and death.<sup>2</sup> The dilemmas among the orthopedic surgeons are to pick the suitable patients to undergo early definitive surgeries and recognize those whose surgeries need to be delayed until stable condition is achieved.<sup>2,3</sup> Our case series are the first to perform a comparison of the treatment results of two polytrauma pediatric patients, classified under the same borderline category who were treated using early total care (ETC) and damage control orthopedics (DCO). The objective of having this case series was to share the short-term outcome of polytrauma pediatric patients who were classified in unstable group managed using two different approaches.

#### METHODS

Two cases of pediatric polytrauma patients were involved in this case series. The patients were classified

as polytrauma after a score was calculated based on the injury severity score (ISS) and abbreviated injury score (AIS) (Table 1). Both of the patients were categorized under borderline group. The first patient underwent early definitive fixation for all the fractures while the second patient had definitive surgeries after stabilization in intensive care unit (ICU). Post operatively we analyzed the duration of intensive care unit admission and ventilation support, numbers and duration of antibiotics usage, post-operative fever and infection and timing of fracture union in both patients.

**CASE 1:** Our first patient was a 4-years-old boy who fell from the third floor and sustained T3/T4 fracture-dislocation with cord edema and complete neurological deficit, bilateral lung contusions, close right distal end radius fracture, close right segmental ulna fracture, close right proximal third humerus fracture, close right midshaft femur fracture and close left intertrochanteric femur fracture (Figure 1). The patient was hypotensive and did not respond to fluid resuscitation on arrival. The blood pressure was maintained with inotropes. According to 'Berlin Definition', this patient had 2 different regions of having scores of at least 3 with systolic blood pressure documented at less than 90mmHg.<sup>4</sup> The ISS was 32 as calculated by the trauma

team. Based on these parameters and treatment received at the initial stage, we classified this patient as unstable. The patient underwent laminectomy and posterior instrumentation of the spine and elastic nail insertion of the right humerus and ulna and bilateral femur ETC on Day 2 of admission.

**CASE 2:** The second patient was an 8-year-old girl who alleged a motor vehicle accident and sustained multiple injuries. She had bilateral lung contusions, close right distal third humerus fracture, close left distal third humerus fracture, close proximal third right femur fracture and open proximal third left femur fracture (Gustilo-Anderson IIIA) (Figure 2). Similar to the previous case, this patient required inotropic supports to elevate the blood pressure at presentation. She was categorized as a polytrauma as she had 2 body regions with scores of 4 with a deep laceration wound at her left thigh (2) making the ISS 36. In addition, the patient was categorized as an unstable patient. The DCO principle was applied for this case. On Day 1 of admission, the patient underwent left thigh wound debridement and bilateral femur external fixation. The patient was stabilized in pediatric ICU, and on Day 6 of admission, definitive surgeries were performed for all the fractures. The patient underwent elastic nail insertion for the bilateral humerus and femur fractures.

## RESULTS

**CASE 1:** Post-operatively, the patient was nursed in pediatric ICU for 26 days after the surgery as he suffered from sepsis secondary hospital-acquired pneumonia and urinary tract infection and needed oxygen support after extubation. After the surgery, the patient required assisted ventilation of continuous positive airway pressure (CPAP), bi-level positive airway pressure (BiPAP) and expiratory positive airway

pressure (EPAP) for 32 days. He developed persistent low-grade fever with right lung consolidation from a plain chest x-ray (Figure 1). The culture and sensitivity from the endotracheal tube grew gram-positive organisms. The urinalysis was suggestive of urinary tract infection, and urine culture and sensitivity grew gram-negative organisms twice. He received five courses of different types of antibiotics for the infections for 31 days in total. He was discharged from the hospital a month later after in-ward rehabilitation. On follow-up, one year after the trauma, all the fractures had achieved union clinically and radiologically. However, there was a minimal improvement of the lower limb weakness and sensory (Table 2).

**CASE 2:** Post-operatively she was nursed in pediatric ICU for 14 days. The patient was extubated four days after the second surgery and given nasal prong oxygen support for another five days. Postoperatively, she developed a low-grade fever that resolved with seven days of two courses of antibiotics. She was discharged well from the hospital after 26 days of admission. She was seen in the clinic three months later, and all fractures had united (Figure 2). At one year after the surgery the patient had returned to her normal function (Table 2).

## DISCUSSION

Polytrauma patients have a high mortality rate and should be managed appropriately. The management of polytrauma patients had evolved from ETC to DCO to prevent 'second hit' effects.<sup>2-5</sup> In the early 1980s, early fixation of the long bones, especially femur fractures, was believed to reduce incidences of Acute Respiratory Distress Syndrome (ARDS), fat embolism, pain, hemorrhage, and coagulopathy that can trigger lethal triad, infection and death, duration of hospital

**Table 1: Abbreviated injury scale (AIS) for different body regions.**

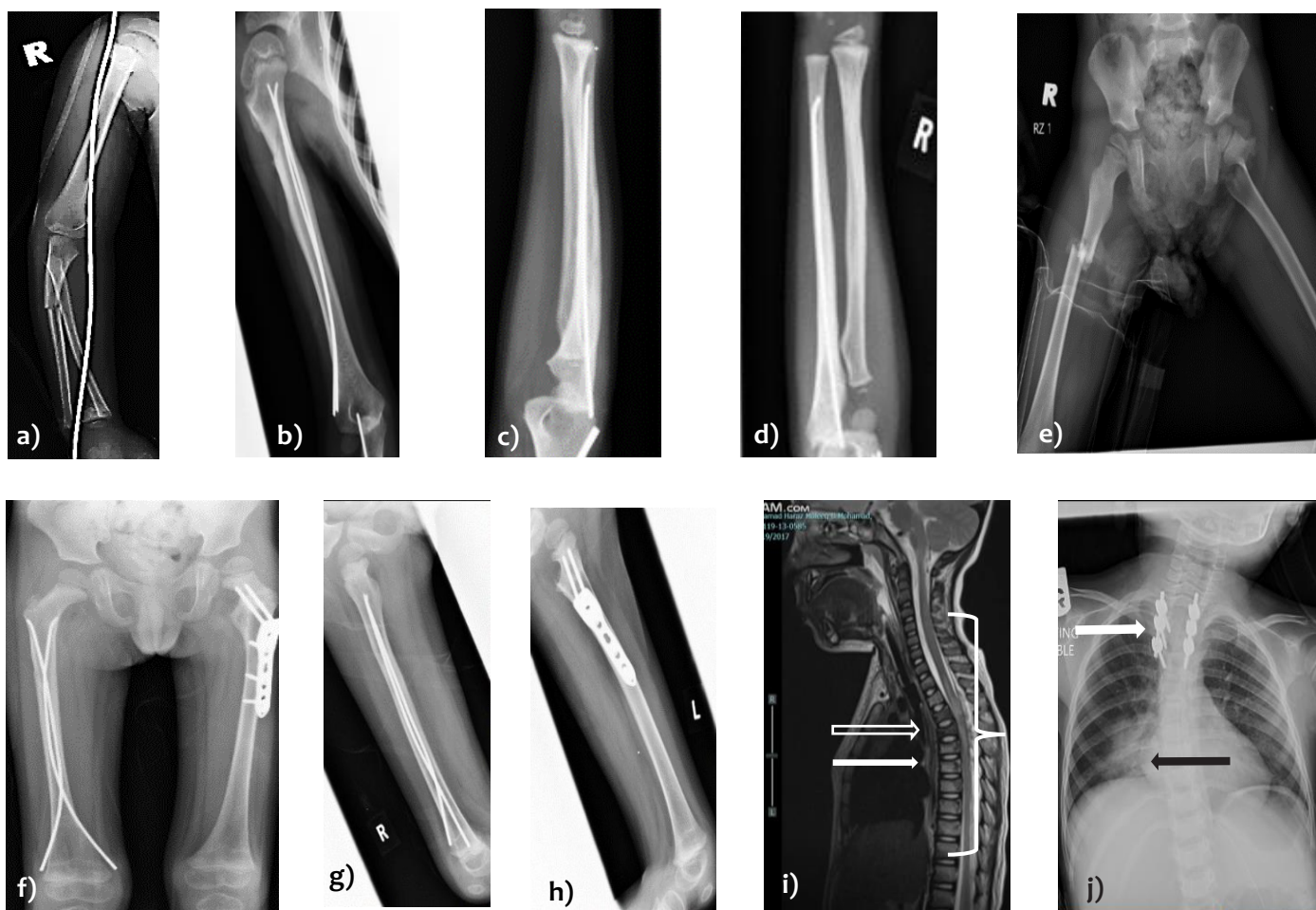
Head or neck	Cervical	AIS 1 – Minor
Face		
Chest	Thoracic spine	AIS 2 – Moderate
Abdominal or pelvic contents	Lumbar spine injury is included	AIS 3 – Serious
Extremities or pelvic girdle	Include sprains, fractures, dislocations and amputations	AIS 4 – Severe
External	Laceration, contusion, abrasions, and burns, independent of the location on the body surface	AIS 5 – Critical
		AIS 6 – Unsurvivable

Injury severity scale (ISS) is calculated as the sum of the squares of the highest AIS code in each of the three most severely injured ISS body region. ISS ranges from 1-75. If an injury is assigned an AIS of 6, the ISS score is automatically assigned 75. A polytrauma case is defined as when the ISS is more than 16.

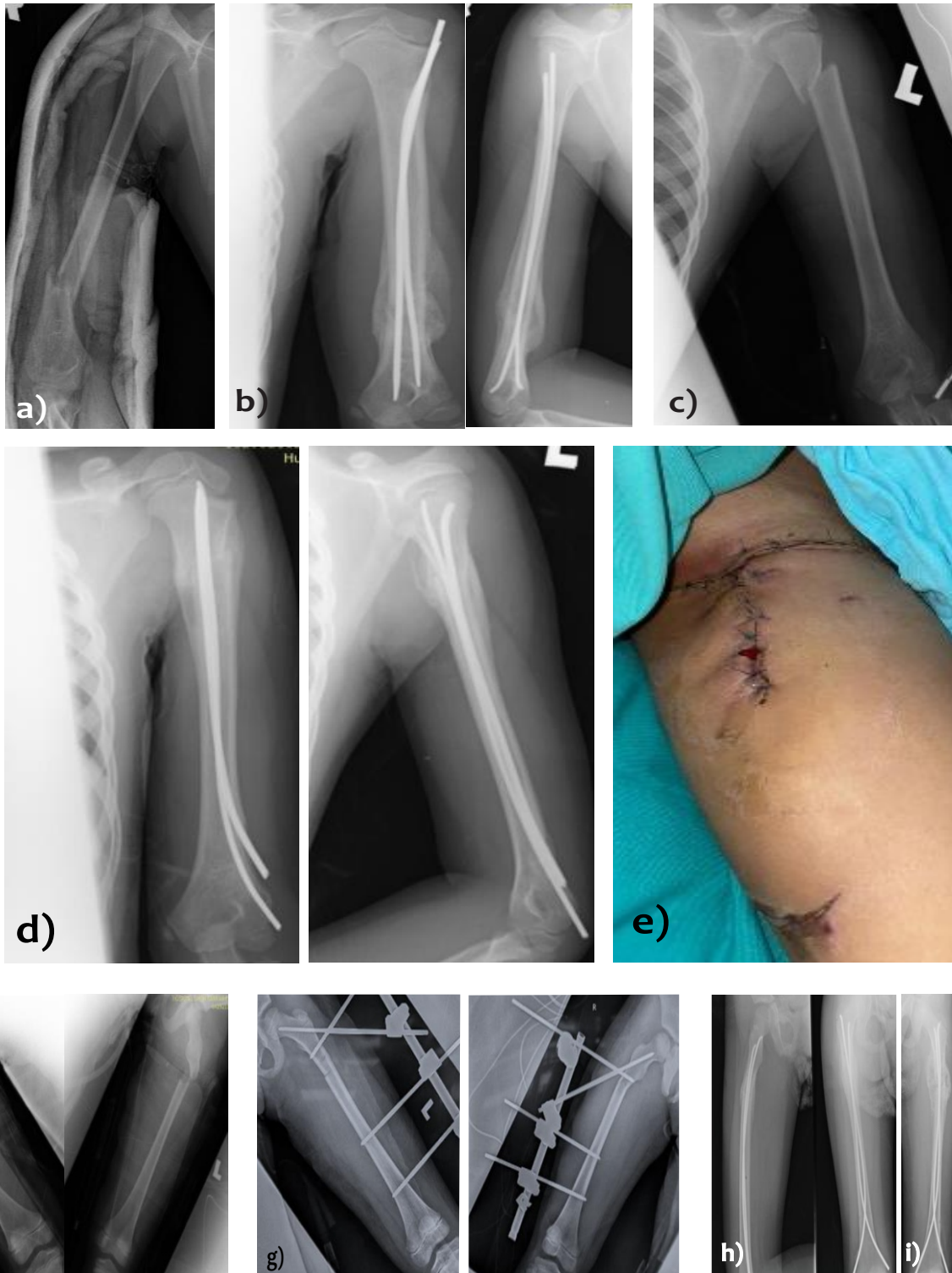
**Table-2: Brief characteristic of the patients.**

Patient	ISS score and classification	Time of surgery	Total days of ICU admission	Duration of ventilation support	Numbers of antibiotics	Duration of antibiotics	Post-operative fever	Infection	Fracture union
1	ISS: 32 borderline	day 2 of admission (ETC)	26 days	32 days	5	31 days	14 days	pneumoniae UTI	12 weeks
2	ISS: 36 borderline	Day 1 and day 6 (DCO)	14 days	5 days	2	7 days	3 days	nil	12 weeks

ETC: Early total care, DCO: Damage control orthopedic, UIT: Urinary tract infection, ISS: Injury severity score, ICU: Intensive care unit



**Figure 1:** (a) The X-Ray shows a segmental ulna and distal third right radius with proximal third humerus fracture, (b) X-ray of the humerus fracture that was addressed using Titanium Elastic Nails (TENS) three months after surgery show united fracture, (c) and (d) Postoperative anteroposterior and lateral x-rays of the radius-ulna taken three months after surgery demonstrated union of the fractures. TENS nail was used to fix the ulna while k-wires that was used to fix the radius had been removed at six weeks post fixation, (e) The immediate anteroposterior pelvic radiograph displays right proximal third and left subtrochanteric fractures, (f), (g) and (h) postoperative anteroposterior and lateral views of bilateral femur x-rays performed three months post-surgery demonstrating fractures union, (i) sagittal cut of the upper spine Magnetic Resonance Imaging (MRI) shows spinal epidural hematomas from T1-T12 (white brace), worst at T3-T5 (white arrow) level causing spinal compression (j) Posteroinferior chest x-ray views show consolidation at right middle and lower zone of the lung (black arrow) corresponding with nosocomial pneumonia, with spinal instrumentation implants in situ (white arrow).



**Figure 2:** (a) Immediate and (b) three months postoperative radiograph of right humerus show a distal third humerus fracture that had achieved union, (c) Initial x-ray of left humerus demonstrates a proximal third humerus fracture that had united after three months post-surgery (d), (e) The patient sustained jagged laceration wound over proximal left thigh that communicated with the left proximal third femur fracture, at the same time she also had close right proximal third femur fracture as well (f), (g) Bilateral femur external fixation were performed for the femur fractures following the Damage Control Orthopaedic principals while the upper limb fractures were immobilized using splints, (h) and (i) The anteroposterior and lateral radiographs of the bilateral femur taken three months after injury. Titanium Elastic Nails were inserted after patient was stabilized in intensive care unit. Radiographical union was demonstrated.

admission and cost of medical care.<sup>2,4</sup> However, in the 1990s DCO principle was introduced since early long definitive surgeries with blood loss presumably can trigger excessive inflammatory responses that can lead to systemic inflammatory responses syndrome (SIRS), ARDS and multiorgan dysfunction syndrome (MODS).<sup>5</sup> The approach stresses splinting the long bone and pelvic fractures with temporary external fixators while addressing other life-threatening injuries and controlling the hemorrhage first, such as intraabdominal injuries, wounds and fasciotomies.<sup>3,5</sup> DCO comprises three important stages: early control of hemorrhage and temporary long bone fixations, stabilization of patients in the intensive care unit, and finally bringing the patients back to the operation theater for definitive osteosynthesis once the condition is met.<sup>3</sup> There was minimal evidence regarding the outcomes of ETC and DCO in polytrauma pediatric patients. Mooney JF et al. described the feasibility of DCO in two cases of pediatric patients who had polytrauma and had open segmental femur fracture, respectively. The open femur fractures were initially treated using DCO principal with spanning external fixation and subsequently followed by submuscular bridge plating masquetelet technique once they were stabilized.<sup>1</sup> Horst K et al in 2019 mentioned that majority of 316 polytrauma pediatric patients in Germany received ETC. They suggested that rate of mortality as well as post-operative complications such as sepsis and multiorgan failure did not show any significant difference to adult patients.<sup>6</sup>

Polytrauma injury stimulates SIRS. There will be a production of inflammatory cytokines like TNF- $\alpha$ , ILN-1 and ILN 6 that will mediate the release of free oxygen radicals and proteases. Subsequently, this will cause damage to the endothelial cells leading to an increase in vascular permeability and interstitial edema. Once the reaction occurs in the lungs tissues, it can lead to ARDS. If multiple organs are involved, it is called MODS.<sup>5</sup> The timing of definitive surgeries is crucial. It was made clear that they should be performed between Day 5 and Day 10 or after three weeks after the trauma. Between Day 2 and Day 4, the inflammatory responses are rapidly ongoing.<sup>5</sup> Patients who had definitive osteosynthesis performed within this period were found to develop MODS compared to those who had them performed later.<sup>5</sup> However, too much delay could potentially expose the patients at risk of developing complications related to pin sites contamination and sepsis.<sup>1,5</sup>

At present, there is no consensus on the proper definition of polytrauma. Previously a patient was categorized as polytrauma when the ISS equals or more

than 16 (Table 1). The ISS is calculated as the sum of the squares of the highest AIS code in each of the three most severely injured ISS body regions.<sup>7</sup> Pape et al. had suggested that polytrauma is defined as an AIS that equals two or more than three for two or more body regions with an additional one or more variables from five physiologic parameters.<sup>7</sup> With reference to ISS definition, polytrauma is defined when the score is equal or more than 16, applicable to adults and paediatric patients.<sup>8</sup> Brown JB et al evaluated the ISS for pediatric patients and suggested that ISS of more than 25 is more appropriate to define a severe trauma injury for paediatric patients.<sup>9</sup> The calculated ISS score was 41 and 28 for our cases indicating a severe trauma injury that necessitate appropriate care in a highly equipped tertiary hospital.

According to Pape et al. polytrauma patients are further classified into four groups.<sup>7</sup> The unstable and in extremis group are managed using DCO. For a patient in extremes, the temporary fixation should be performed in ICU. The stable group can be treated with ETC, where the definitive surgeries can be performed primarily.<sup>2,4</sup> The main discussion is on the borderline group in which there is no consensus on either ETC or DCO as the preferred option. Pape et al. defined the borderline group as the patients who initially respond to the resuscitation but subsequently deteriorate and may develop multiple organ dysfunction.<sup>7</sup> The borderline group is also defined based on a few criteria and will be reevaluated based on the overall condition and response to resuscitation.<sup>7</sup> Both of our patients required vasopressors to maintain the blood pressure within the normal range as they were hypotensive at presentation.

Care of the patients is best managed by a multidisciplinary team in a pediatric-verified trauma center with experience in treating complex injuries.<sup>10</sup> Schlegel et al mentioned patients transition to specialized pediatric trauma center was proven to be safe and lead to improved mortality rate and treatment outcome.<sup>10</sup> In our setting both patients were treated in a tertiary center with qualified personnel consists of multiple medical subspecialties that include pediatric orthopedic surgeons, pediatric intensivists, anesthesiologists and rehabilitation physicians.

Our case series are the first to compare the outcome of two polytrauma pediatric patients classified in the same category who had different treatment approach. The surgeon decided to perform definitive surgeries for the first case while the DCO principle was applied to manage the second case. Interestingly we encountered different outcomes for both patients who were

categorized in the unstable group. One of them who had ETC suffered from sepsis secondary right-sided hospital-acquired pneumonia requiring prolonged ICU care and hospital admission. The other patient who had definitive surgeries after stabilization had a faster recovery and shorter hospital stay (Table 2). However, we believe that more cases should be included in the study in the future to strengthen our theory. The other limitation is that the comparison of the outcome of these patients is a challenging process as each patient suffers from different type and severity of injury and often categorized to different groups that are non-comparable. The strength of our series is that it evaluates the treatment result of two cases of similar category and had almost identical ISS score with relatively equivalent anatomical regions involved.

## CONCLUSION

Adult polytraumatized patients can be managed either using DCO principle or ETC depending on the patient's condition, as described in many literatures. From our case series of two pediatric cases, more complications were encountered in patients who received ETC, namely sepsis with hospital-acquired pneumonia and urinary tract infection that required prolonged ventilation, multiple and longer, antibiotic coverage and intensive unit care. In conclusion, based to the case series, for a polytraumatized child, the initial surgery needs to be kept at a minimum with short operating time to prevent further deterioration. Stabilization in the ICU is mandatory before definitive surgeries can commence. The approach to a polytrauma patient should be multidisciplinary and involvement of an expert paediatric intensivist is essential to ensure good outcome.

Received: June 24, 2022

Accepted: November 15, 2022

## REFERENCES

1. Mooney JF. The use of 'damage control orthopedics'

techniques in children with segmental open femur fractures. *J Pediatr Orthop B* 2012; 21: 400-3.

[doi:10.1097/BPB.0b013e32834fe897](https://doi.org/10.1097/BPB.0b013e32834fe897)

2. Jordan RW, Chahal GS, Davies MH. Role of damage control orthopedics and early total care in the multiple injured trauma patients. *Clin Med Insights: Trauma Intens Med* 2014; 15: 15-8.  
[doi:10.4137/CMTIM.S12258](https://doi.org/10.4137/CMTIM.S12258)
3. Nicola R. Early total care versus damage control: current concepts in the orthopedic care of polytrauma patients. *ISRN Orthop* 2013; 2013:329452.  
[doi:10.1155/2013/329452](https://doi.org/10.1155/2013/329452)
4. Guerado E, Bertrand ML, Cano JR, Cervan AM, Galan A. Damage control orthopaedics: State of the art. *World J Orthop* 2019; 10:1-13.  
[doi:10.5312/wjo.v10.i1.1](https://doi.org/10.5312/wjo.v10.i1.1)
5. Philipson M R, Parker PJ. Damage control orthopaedics. *Trauma* 2007; 9:245-54.  
[doi:10.1177/1460408607088042](https://doi.org/10.1177/1460408607088042)
6. Horst K, Andruszkow H, Weber CD, Pishnamaz M, Knobe M, Blasius FM, et al. Surgical treatment strategies in pediatric trauma patients: ETC vs. DCO-an analysis of 316 pediatric trauma patients from the Trauma Register DGU. *Eur J Trauma Emerg Surg* 2019; 45:801-8.  
[doi:10.1007/s00068-019-01092-7](https://doi.org/10.1007/s00068-019-01092-7)
7. Pape HC, Lefering R, Butcher N, Peitzman A, Leenen L, Marzi I, et al. The definition of polytrauma revisited: international consensus process and proposal of the new 'Berlin definition'. *J Trauma Acute Care Surg* 2014; 77:780-6.  
[doi:10.1097/TA.000000000000453](https://doi.org/10.1097/TA.000000000000453)
8. Weber B, Lackner I, Braun CK, Kalbitz M, Huber-Lang M, Pressmar J, et al. Laboratory markers in the management of pediatric polytrauma: Current role and areas of future research. *Front Pediatr* 2021; 9:622753.  
[doi:10.3389/fped.2021.622753](https://doi.org/10.3389/fped.2021.622753)
9. Brown JB, Gestring ML, Leeper CM, Sperry JL, Peitzman AB, Billiar TR, et al. The value of the injury severity score in pediatric trauma: Time for a new definition of severe injury? *J Trauma Acute Care Surg* 2017; 82:995-1001.  
[doi:10.1097/TA.0000000000001440](https://doi.org/10.1097/TA.0000000000001440)
10. Schlegel C, Greeno A, Chen H, Raees M A, Collins KF, Chung DH, et al. Evolution of a level I pediatric trauma center: Changes in injury mechanisms and improved outcomes. *Surgery* 2018; 163:1173-7.  
[doi:10.1016/j.surg.2017](https://doi.org/10.1016/j.surg.2017)