

## Partial Cholecystectomy: Indications and Outcomes

Abdul Ghani, Waqar Ahmed and F.U. Baqai

### ABSTRACT

**Objective:** To analyse the indications, frequency and outcomes of open partial cholecystectomy in comparison with complete cholecystectomy during surgery.

**Material & Methods:** A retrospective descriptive study was performed at the Department of Surgery, Baqai Medical University Hospital, Nazimabad, Karachi from April 2007 to April 2012. A total number of 42 patients with gall stone disease, who underwent partial cholecystectomy, were analysed. The case selection criteria was based preoperatively on history, clinical findings, ultrasound and CT scan examination. Final decision was made as per operative findings during open cholecystectomy.

**Results:** Forty two (42) patients with gall stone disease underwent partial cholecystectomy. Age range was from 35 years to 80 years (Mean age: 47 years). Male and female ratio showed female preponderance. In our study, 62% patients had acute cholecystitis, 16.5% patients had empyema gall bladder, 9.5% patients had mucocele and 12% patients had gall stone acute pancreatitis. Tube Cholecystostomy was performed in two patients.

**Conclusion:** Partial cholecystectomy is safe and effective procedure in difficult cases, with over all less complications and is almost equivalent to total cholecystectomy.

**Key words:** Open cholecystectomy (OP), Laparoscopic cholecystectomy (LC) Open partial cholecystectomy (OPC) Laparoscopic partial cholecystectomy (LPC), Tube cholecystostomy (TC), Gall bladder disease, Cholecystitis., MRCP (magnetic resonant cholangiopancreatography.) ERCP (endoscopic retrograde cholangiopancreatography) C.T (computerized tomography) CBD (Common bile duct).

How to cite this article: Ghani A, Ahmed W, Baqai FU. Partial Cholecystectomy: Indications and Outcomes. J Dow Uni Health Sci 2013; 7(3): 107-111.

### INTRODUCTION

The incidence of cholelithiasis increases with age. At age 60 years approximately 25% of women and 12% of men in USA have gall stones but in some countries e.g. Sweden, Chile & ethnic groups (e.g. Pima Indians) the incidence of gall stones may approach 50%.<sup>1,2</sup>

The best screening method to accurately diagnose prevalence of gallstone disease is ultrasonography which is having, 90 to 95% sensitivity, it is non invasive and safe method.<sup>3-5</sup> About 80% of patients with gall stones are asymptomatic. Each year about 2% of patients will develop symptoms and this usually results from obstruction of cystic duct by a stone impacted in Hartmann's pouch and these patients will need cholecystectomy which is one of the most common operations performed by the general surgeons.<sup>6,7</sup>

Diabetic and older patients are particularly prone to gangrenous & emphysematous Cholecystitis.<sup>8</sup> Male

patients with acute cholecystitis are older, have more co morbidities and more likely to have gangrenous cholecystitis than female patients.<sup>10</sup> Acute cholecystitis was associated with greater operative difficulty and more postoperative morbidity than chronic Cholecystitis.<sup>11</sup>

With the advent of Laparoscopic era the trend has moved to Laparoscopic cholecystectomy (LC) and most of the operations are being done by this method. However since the introduction of LC, an increased rate (20-50%) of cholecystectomies has been documented.<sup>12,13</sup> It is not possible to do LC in patients who have had an open operations for upper abdominal surgery for peritonitis plus severe adhesions, cholangitis, and the patients refusal of open cholecystectomy should urgent conversion be required.<sup>1</sup>

Open cholecystectomy is mostly performed in those patients who have contraindications for LC or require conversion from LC because of inability to complete the procedure and also in patients suffering from Mirizzi Syndrome<sup>14</sup> and also patients suffering from Xanthogranulomatous cholecystitis.<sup>15</sup>

During cholecystectomy OC or LC, at times there is excessive inflammation, fibrosis & increased vascularity

---

Baqai Medical University Hospital, Karachi, Pakistan.

**Correspondence:** Professor Waqar Ahmed, Baqai Medical University Hospital, Karachi, Pakistan.

E-mail: drwaqar42@yahoo.com

which makes the dissection of calot triangle difficult & there is high risk of damage to the biliary system or damage to the hepatic vessels. In these circumstances, the safest procedure in our opinion would be partial cholecystectomy. Partial cholecystectomy is often performed procedure and well documented in literature.<sup>16-19</sup>

The objective of our study was to find out the frequency, indications and outcomes of open partial cholecystectomy in our hospital and whether it was an effective, safe procedure and cost effective.

## METHODS AND MATERIALS

A retrospective descriptive study was performed at the department of surgery, Baqai Medical University Hospital, Nazimabad, Karachi from April 2007 to April 2012. The Ethics Committee of Baqai Medical University approved the study. Informed written consent was obtained from each patient. Patients were admitted through out patient's dept and emergency department to the department of Surgery. The following selection criteria was employed, all cases of acute cholecystitis including interval and urgent cholecystectomy, patients who underwent conversion from LC to OC, patients with gall stone pancreatitis and those with chronic cholecystitis.

Exclusion criteria included those patients who had cholelithiasis with common bile duct (CBD) stones, carcinoma of gall bladder and cholangiocarcinoma. Diagnosis was based on clinical assessment, supported by ultrasonography. CT- Scan and MRCP were carried out in selected cases. CT scan was done in two Patients and MRCP in one Patient where the ultrasound findings were inconclusive of the underline pathology. All co-morbidities were paid special attention to before subjecting patients to cholecystectomy.

### Operative procedure:

Partial Cholecystectomy was performed through Kocher's incision. Per operative decision for partial cholecystectomy was made when it was not possible to isolate cystic duct, cystic artery and CBD on account of dense adhesions around the Calot's triangle.<sup>16-19</sup>

The gall bladder was opened; all its contents including stones, debris and pus were removed, and it was then washed with normal saline. The distal gallbladder was excised through the Hartmann's pouch and margins were closed with a continuous 2/0 vicryl suture. The posterior strip of gall bladder adherent to liver was left and its mucosa was electro coagulated with diathermy.

A tube drain was placed in sub hepatic space and was removed when neither fluid nor bile drained through it (3 to 6 days) and then patient was discharged on the day that the tube was removed. The operative details, postoperative complications and outcome were noted.

Tube cholecystostomy was performed when further dissection around the gall bladder was difficult or when the gall bladder was adherent to colon, omentum or duodenum. In this procedure all the stones were removed through fundus of the gall bladder and closed over wide bore tube.<sup>1</sup> The tube was removed after obtaining satisfactory tube cholangiogram.

All patients were provided coverage with broad spectrum antibiotics. Parental ceftriaxone 1 gm., twice a day with Metronidazole 500 mg thrice a day was administered post operatively for 5 days.

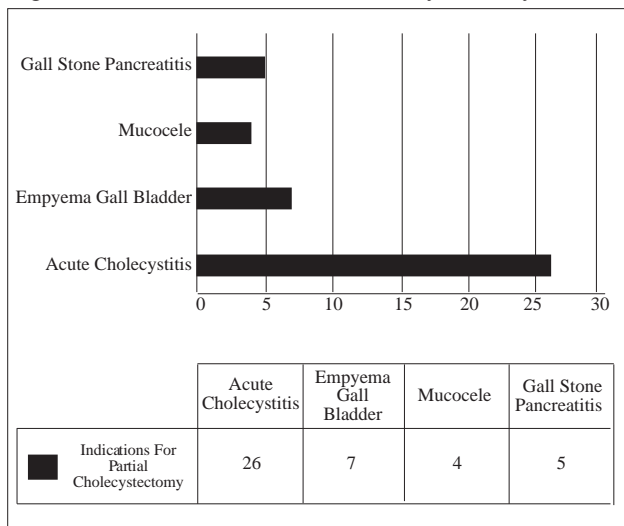
## RESULTS

In this study, a total of 42 patients underwent partial cholecystectomy among 280 laparoscopic and open cholecystectomy procedures. Majority of the patients who underwent the procedure were female- 40 (95%), while 2 (5%) patients were male. The age range was 35-80 (mean 47) years. Out of total, 26 (62%) patients had acute cholecystitis, 7(16.5%) patients had empyema gall bladder, 4(9.5%) patients had mucocele of the gall bladder and 5 (12%) patients had gall stone pancreatitis. In two patients tube cholecystostomy was employed and after an interval of 12 weeks, open cholecystectomy was performed. In our study, 29(69%) had diabetes mellitus, 20(47.5%) had hypertension, 12 (28.5%) had ischemic heart disease and 16(30%) patients had both DM and HTN. The patients were followed up every three month initially and then every six months contact was made either by telephone or by writing to them. On each visit Liver Function Tests and ultrasound examination was carried out. To date, none of our patients have had any post-operative complications attributable to partial cholecystectomy.

FIGURE 1: PATIENTS' DEMOGRAPHICS

PATIENTS' DEMOGRAPHICS	
GENDER DISTRIBUTION:	TOTAL (%)
Females	40 (95)
Males	2 (5)
AGE RANGE	35- 80 years (47 years)
CO-MORBIDITIES	TOTAL (%)
Diabetes Mellitus (DM)	29 (69)
Hypertension (HTN)	20 (47.5)
DM + HTN	16 (30)
Ischemic Heart Disease	12 (28.5)

Figure 2: Indications For Partial Cholecystectomy



## DISCUSSION

There are two schools of thought in managing patients, of gallstones/acute cholecystitis. One is that if the patient presents within 72 Hours of the onset of symptoms of acute cholecystitis then cholecystectomy should be performed. After 72 hours then the patient should be managed on conservative lines with I/v Fluids, appropriate antibiotics plus analgesics. Once the acute attack has resolved then patient is advised surgery after 6 to 12 weeks.

Conservative treatment must be abandoned if the pain and tenderness increase then surgery should be performed. If the patient has serious comorbid conditions then a percutaneous cholecystostomy be performed under ultrasound control which will rapidly relieve symptoms and cholecystectomy to be done at a later time when the patients general condition has improved.<sup>1</sup>

In our study, majority of patients had acute cholecystitis and empyema gallbladder. In acute cholecystitis usually an interval cholecystectomy is employed at 6-12 weeks after resolution of acute episode. It is documented, in the first 72-92 hours of acute Cholecystitis, the inflammatory changes around the gall bladder tend to be oedematous and the tissue planes preserved thus facilitating removal of the gall bladder. After this time frame, the acute inflammatory reaction progress and mature with fibrotic changes and obliterating tissue planes.<sup>20</sup>

In gall stone pancreatitis there were dense adhesions around calot's triangle; therefore, partial cholecystectomy was employed to avoid CBD injury. The most common of benign biliary stricture is iatrogenic bile duct trauma during cholecystectomy. Despite the expertise gained worldwide in LC, the overall incidence of injury to the bile duct is

approximately twice as high as that following open cholecystectomy.<sup>21</sup> In our study there was no cystic duct and CBD injury, no biliary leak and no mortality. In addition to the biliary leak the other complications reported are sub hepatic abscess, retained stones ,recurrent symptoms, wound infections, persistent biliary fistula and prolonged biliary drainage and with an overall mortality rate of 9.4 per cent.<sup>17,19</sup> For the retained stones in Common Bile duct and biliary fistula/prolonged biliary drainage further intervention had to be carried out like ERCP, Stenting/ sphincterotomy to remove stones from common bile duct.<sup>15-18</sup>

In the United States, the graduating chief surgical resident now performs an average of 90 laparoscopic cholecystectomies, where as he does only 12 open cholecystectomies and less than two common bile duct explorations. In the near future these open biliary surgery operations will be performed by surgeons who have limited experience in complex biliary (and other open) operation as the seasoned biliary surgeons leave practice. This scenario has yet to come to fruition, however and bile duct injuries are still twice as likely to develop after laparoscopic than open cholecystectomy.<sup>22</sup>

The surgical trend for complex acute cholecystitis treatment has changed that previously only cholecystostomy was done in acute cases of cholecystitis where calot's triangle structures were grossly inflamed and now OPC or LPC are being done.

Partial cholecystectomy in elective and emergency gall bladder surgery is a viable and safe option whether done by the open method or laparoscopically. It has been described in literature since 1985 (and probably earlier). It is an attempt to prevent iatrogenic common bile duct injury with OPC or LPC.<sup>23</sup>

In one study of early LC for acute cholecystitis they found no significant difference in converting to open cholecystectomy but found that there was significant more blood loss, more operating time but shorter stay in hospital<sup>20</sup> whereas another study suggested that early operation (open or laparoscopic) does not carry a higher risk of mortality or morbidity compared to delayed operation and should be the preferred surgical approach for patients with acute lithiasic cholecystitis.<sup>24</sup>

There are four cases reported who after PC (two of OPC and two of LPC) who presented with biliary pancreatitis within 12 to 24 months of the surgery. They were investigated and all four cases were again operated upon laparoscopically and the remaining portion of the gallbladder was removed and they have been free of symptoms since then.<sup>25</sup>

In one case reported of recurrent acute cholecystitis and choledocholithiasis following OPC. The operation was first attempted LC but then converted to open. Here again because of severe inflammation and anatomical abnormalities OPC was done with a surgical TA stapler across the infundibulum leaving about 25 % of the gall bladder including the cystic duct. He kept on having severe pain plus jaundice and he was investigated and was found to have dilated CBD with stones in it plus stones in the gall bladder stump. He was operated upon by the open method by the reporting author and there were a lot of adhesions and the gall bladder stump left behind was intra hepatic and located at the most inferior portion of the liver. It was possible on this occasion to remove the remaining gall bladder after ligating the cystic duct and artery. The authors feel that all efforts should be made to remove remaining gall stones from the remaining portion of the gall bladder as this was not done in this patient and this explains the lack of recovery from OPC.<sup>26</sup> For his stones in CBD he had ERCP and sphincterotomy which was done pre operatively to extract the remaining common bile duct stones.

Successful repair of bile duct injuries after cholecystectomy can be better achieved in specialized hepato-biliary units<sup>21</sup> Incidence of bile leak after open cholecystectomy was 2.6 % in this study and in gangrenous cholecystitis the incidence of bile leak was 24%.<sup>27</sup>

## CONCLUSION

Partial Cholecystectomy has been found to be a safe and effective procedure in difficult cholecystectomy situations since it combines the merits of cholecystostomy and cholecystectomy. It is an alternative and equivalent to total cholecystectomy in such cases as it is safer, of shorter duration and little blood loss during surgery and good long term outcome.

## REFERENCES

- Pierce RA, Strasberg SM. Biliary Surgery. The Washington's Manual of Surgery 5<sup>th</sup> Edition 2009; 15: 264-7.
- Tazuma S. Gallstone disease: Epidemiology, pathogenesis, and classification of biliary stones (common bile duct and intrahepatic). *Best Pract Res Clin Gastroenterol* 2006; 20: 1075-83.
- Stinton LM, Shaffer EA. Epidemiology of gallbladder disease: cholelithiasis and cancer. *Gut Liver* 2012; 6: 172-87.
- Schirmer BD, Winters KL, Edlich RF. Cholelithiasis and cholecystitis. *J Long Term Eff Med Implants* 2005; 15: 329-38.
- Stinton LM, Myers RP, Shaffer EA. Epidemiology of gallstones. *Gastroenterol Clin North Am* 2010; 39: 157-69.
- Conlon K. Bailey's and love; Short practice of Surgery. 25 ed. The gallbladder and bile duct, ed. P.R.O. Connell. 2008: CRC Press. 1119 – 26.
- Doherty GM. Current Diagnosis and Treatment Surgery. 13 ed. 2006: The McGraw-Hill Companies, Inc. 553 – 55.
- Kuwabara K, Matsuda S, Fushimi K, Ishikawa KB, Horiguchi H, Fujimori K. Relationships of age, cholecystectomy approach and timing with the surgical and functional outcomes of elderly patients with cholecystitis. *Int J Surg* 2011; 9: 392-9.
- Bloom AA, Leon Pachter H, Parik M, Remy P, Cagir B. Emphysematous Cholecystitis. <http://emedicine.medscape.com/article/173885-overview> cited on 8/26/2013.
- Nikfarjam, M, Harnaen E, Tufail F, Muralidharan V, Fink M, A., Starkey G et al., Sex differences and outcomes of management of acute cholecystitis. *Surg Laparosc Endosc Percutan Tech*, 2013. 23(1): 61-5.
- Cho JY, Han HS, Yoon YS, Ahn KS. Risk factors for acute cholecystitis and a complicated clinical course in patients with symptomatic cholelithiasis. *Arch Surg* 2010; 145: 329-33.
- Festi D, Reggiani ML, Attili AF, Loria P, Pazzi P, Scaiola E et al. Natural history of gallstone disease: Expectant management or active treatment? Results from a population-based cohort study. *J Gastroenterol Hepatol* 2010; 25: 719-24.
- Legorreta AP, Silber JH, Costantino GN, Kobylinski RW, Zatz SL. Increased cholecystectomy rate after the introduction of laparoscopic cholecystectomy. *JAMA* 1993; 270: 1429-32.
- Safioleas M, Stamatakos M, Safioleas P, Smyrnis A, Revenas C, Safioleas C. Mirizzi Syndrome: an unexpected problem of cholelithiasis. Our experience with 27 cases. *Int Semin Surg Oncol*, 2008. 5: 12.
- Srinivas GN, Sinha S, Ryley N, Houghton PW. Perfidious gallbladders - a diagnostic dilemma with xanthogranulomatous cholecystitis. *Ann R Coll Surg Engl* 2007; 89: 168-72.
- Cakmak A, Genc V, Orozakunov E, Kepenekci I, Cetinkaya OA, Hazedaroglu MS, Partial cholecystectomy is a safe and efficient method. *Chirurgia (Bucur)* 2009; 104: 701-4.
- Sharp CF, Garza RZ, Mangram AJ, Dunn EL. Partial cholecystectomy in the setting of severe inflammation is an acceptable consideration with few long-term sequelae. *Am Surg* 2009; 75: 249-52.
- Davis B, Castaneda G, Lopez J. Subtotal cholecystectomy versus total cholecystectomy in complicated cholecystitis. *Am Surg* 2012; 78: 814-7.

- 19 Soleimani MA, Mehrabi A, Mood ZA, Fonouni H, Kashfi A, Buchler M et al. Partial cholecystectomy as a safe and viable option in the emergency treatment of complex acute cholecystitis: a case series and review of the literature. *Am Surg* 2007; 73: 498-507.
- 20 Gul R, Dar RA, Sheikh RA, Salro NA, Matoo AR. Comparison of early and Delayed laparoscopic cholecystectomy for acute Cholecystitis experience from single centre. *North Am J Med Sci* 2013; 5:414-8.
- 21 Schmidt S, Langrehr JM, Hintze RE, Neuhaus P. Long-term results and risk factors influencing outcome of major bile duct injuries following cholecystectomy. *Br J Surg*, 2005; 92: 76-82.
- 22 McAneny D. Open cholecystectomy. *Surg Clin North Am* 2008; 88: 1273-94.
- 23 Lee J, Miller P, Kermani R, Dao HO, Donnell K. Gallbladder damage control: compromised procedure for compromised patients. *Surg Endosc* 2012; 26: 2779-83.
- 24 Papi C, Catarci M, D'Ambrosia L, Gili L, Koch M, Grassi GB et al. Timing of cholecystectomy for acute calculus cholecystitis; Ameta analysis. *Am J Gastroenterol* 2004; 99: 147-55.
- 25 Hussain M, Nagral S. Biliary pancreatitis secondary to stones from a gall bladder remnant. *Trop Gastroenterol* 2010; 31: 230-3.
- 26 Sosulski AB, Fei JZ, DeMuro JP. Partial cholecystectomy resulting in recurrent acute cholecystitis and choledocholithiasis. *JSCR* 2012; 9: 17.
- 27 Arroyo K, Bonadies J, Ciardiello K. Bile leak in open cholecystectomy: related to gangrenous cholecystitis? *Conn Med* 2010; 74: 329-31.

