

Giant Right Inguinal Hernia in Female Patients Over 60 Years of Age

Naveed Ali Khan, Daleep Kumar, Amna Bhatti, Amjad Siraj Memon

ABSTRACT

Inguinal hernia are by far the most common variety of hernia in adults. While abit more common in men they do occur in women as well with male to female ration of 12:1. Here in we report a case of giant direct inguinal hernia in thin lean post menopausal women.

Key words: Giant, inguinal hernia.

How to cite this article: Khan NA, Kumar D, Bhatti A, Memon AS. Giant Right Inguinal Hernia in Female Patients Over 60 Years of Age. J Dow Uni Health Sci 2014; 8(3): 134-135.

INTRODUCTION

Abdominal wall hernia constitute one of the most common surgical entity¹. They are leading cause of disability and even lethal at times. Knowledge of hernias of the abdominal wall both usual and unusual and their pretenders are essential components of the armamentarium of the general and pediatric surgeon^{1,2}. Hernia is a very common medical condition afflicting all ages and both sexes. Hernia is a weakening in the abdominal wall. Currently adult herniorrhaphy accounts for 15% of total general surgical procedures^{1,4}. Approximately 756,000 hernia repairs were completed in United States in 1996⁵. These hernias may be a congenital defect or acquired as a result of repeated trauma. Hernia most commonly presents as a bulge under the skin, sometimes accompanied with pain during lifting heavy objects⁴. As much as 10% of the population develops some type of hernia during life. Diagnosis of inguinal hernia is clinical and can be categorized according to the extent in complete and incomplete⁶. We hereby report case of an old women with huge inguinal hernia being a rare entity in females.

Case Report:

65 years old women, presented in OPD with a painless swelling in right inguinal region for the last three years. Swelling was initially small but gradually became huge manually reducible with a palpable defect. There is no

fever, abdominal pain, constipation or vomiting associated with it. Past medical history is unremarkable except that she is postmenopausal. On examination patient had a temperature of 100⁰F, abdomen was unremarkable. Local examination revealed solitary spherical swelling in right inguinal region below and medial to the inguinal ligament with normal overlying skin. Swelling is soft, non fluctuant 12x12 cm spherical with visible peristalsis. Swelling was completely reducible with cough impulse positive. Rest of the systemic examination was unremarkable. Hematological and biochemical investigations were normal. Xray Chest was normal as well so surgery for inguinal hernia was planned. Intraoperative findings included gut protruding through the Hasselbach's triangle and the sac was huge with a wide neck while the contents were omentum and small intestine which were reduced back in the abdominal cavity and the defect was repaired.

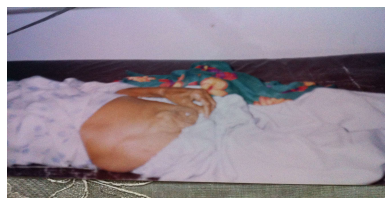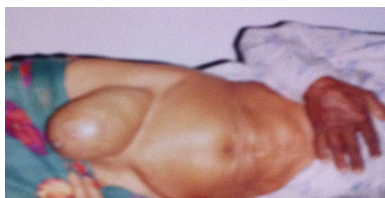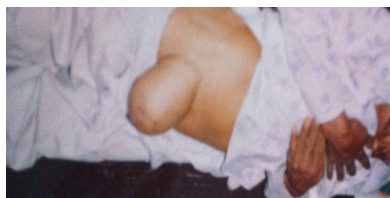
DISCUSSION

Hernia defined as weakening or a defect in the abdominal wall. It is a common surgical condition affecting both sexes. Most common variety being inguinal presents as a bulge in the inguinal region. Hernia in children is proposed to be secondary to patent processus vaginalis. Another proposed theory is persistence of smooth muscles which should undergo programmed cell death after presenting transiently to propel the testis. Because the sac associated with undescended testis are without smooth muscle and herniation is not a frequent association they may not share the same etiological basis with inguinal hernias^{4,5}. According to the prevalence 25% are direct inguinal hernias, 14 % are umbilical and 5 % are femoral^{5,6}. Prevalence of all variety increases with age .

Department of General Surgery, Civil Hospital Karachi, Pakistan.

.....
Correspondence: Dr. Amna Bhatti, Department of General Surgery, Civil Hospital Karachi.

Email: a-bhatti@live.com



Increased intraabdominal pressure secondary to cough, ascites, increased peritoneal fluid from biliary atresia, peritoneal dialysis and ventriculoperitoneal shunt constitute the common causes. Collagen disorders including EhlerDanlos Syndrome, Hunter Hurler, Osteogenesis Imperfecta result in abdominal wall defects. In 1981, Canon and read found that increased serum elastase and decreased alpha -1- antitrypsin in smokers contributes to an increase rate of inguinal hernias. The discomfort with inguinal hernias usually occurs with activity and relieves with rest. Hernia once diagnosed on clinical grounds, evaluation of provocative factors such as prostatism, cough, ascites becomes important⁶. Initially the treatment was debatable with truss causing pressure on skin and bowel, temporary binders, simple herniorrhaphy and hernioplasty. Massive hernias need mesh repair to aid closure and now laparoscopic repair has become widely acceptable and is being practiced worldwide.

Giant inguinal hernias in females are reported very rarely. Recurrence remained an issue previously though the chances are very low with the use of mesh for repair of defects. The case we report had a simple closure but short term followup did not reveal recurrence.

REFERENCES

1. Renou G, Sameul S, Kushner A, Dumbuya S. Three-stage repair of a giant inguinal hernia in Sierra Leone: A management technique for low-resource settings. *JSCR* 2011; 12:8.
2. Anthony T, Bergen PC, Kim LT. Factors affecting recurrence following incisional herniorrhaphy. *World J Surg* 2000; 24:95-100.
3. Tanyel FC, Muftuoglu S, Dagdeveran A, Kaymaz FF. Myofibroblasts defined by electron microscopy suggest the dedifferentiation of smooth muscle within the sac walls associated with congenital inguinal hernia. *BJUI* 2001; 87:251-5.
4. Hodgson NC, Malthaner RA, Ostbye T. The search for an ideal method of abdominal fascial closure : a meta analysis. *Ann Surg* 2000; 231:436-42.
5. Hammad A, Marimuthu K, Mothi B, Hanafy M. Repair of massive inguinal hernia with loss of abdominal domain using laparoscopic component separation technique. *JSCR* 2013; 3:11-2.
6. Hill SJ, Durham MM. An alternative approach for management of the congenital giant inguinal hernia in neonates. *J Pediatr Surg* 2011; 46:10-11.

