

CASE REPORT

CONGENITAL SEGMENTAL DILATATION OF SIGMOID COLON, PENILE AGENESIS AND UMBILICAL CORD HERNIA - A NEW ASSOCIATION

Muhammad Talat Mehmood¹, Farhan Shahzad², Muhammad Sajjad Ashraf³,
Muhammad Shahab Athar¹ and Javed Ahmad⁴

ABSTRACT

Congenital segmental dilatation of the colon, penile agenesis and umbilical cord hernia are individually rare congenital malformations. An association between all three malformations has not been previously reported. We report a neonate with congenital segmental dilatation of the colon, penile agenesis and umbilical cord hernia all coexistent in a new born.

Keywords: Segmental dilatation of Sigmoid Colon, Penile Agenesis, umbilical cord hernia.

INTRODUCTION

Congenital segmental dilatation of the colon is a rare disease. Since its first description by Swenson and Rathausser in 1959, the entity has been reported mostly in children beyond neonatal period.^{1,2} There are only 11 cases of congenital segmental dilatation of the colon in neonates majority of them were associated with anorectal malformations.³⁻¹³

Congenital absence of the penis, or aphallia, is also a rare anomaly with an approximate incidence of 1 in 10 million populations¹⁴ while umbilical cord hernia is very rare and accounts for only 20 % of all the congenital abdominal wall defects.¹⁵ As far as our knowledge is concerned and as per literature search, the occurrence of all three malformations (congenital segmental dilatation of sigmoid colon, penile agenesis, and umbilical cord hernia) in a neonate has not been reported so far. We are reporting it for the first time.

CASE REPORT

A 12 hour old baby presented with absence of penis, abdominal distention, umbilical swelling and bilious vomiting. On physical examination, the abdomen

was distended with visible intestinal loops. A small umbilical swelling about 2 cm. in size covered with sac, along with centrally attached cord (**umbilical cord hernia**). There was absence of penis and no urinary opening could be identified in the perineum. The scrotum was fully developed with well descended testis. Anus was normal. On plain X-ray of abdomen in erect and supine, there were signs of intestinal obstruction. Ultrasound examination revealed bilateral hydronephrotic kidneys with distended urinary bladder and dilated bowel loops.

At laparotomy, segmental dilatation of sigmoid colon was found, 6 cm in length with normal caliber of sigmoid colon proximally and distally. Urinary bladder was also distended. Colostomy, proximal to dilated sigmoid colon, vesicostomy and repair of umbilical cord hernia was performed (Figure 1).

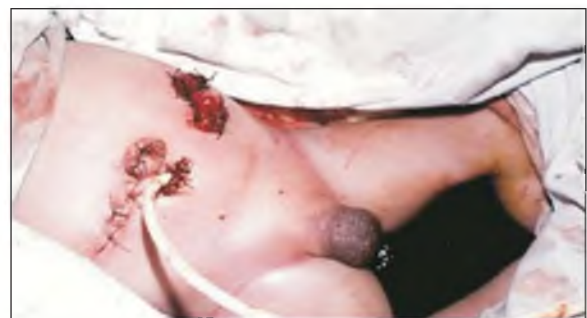

Figure 1: Photograph showing absent penis, suprapubic vesicostomy & sigmoid colostomy

1. Paeds Surgery, Dow Medical College/Civil Hospital, Karachi, Pakistan.

2. Paeds Surgery, Civil Hospital, Karachi, Pakistan.

3. Surgical Unit I, Dow Medical College/Civil Hospital, Karachi, Pakistan.

4. Surgical Unit VII, Dow Medical College/Liary General Hospital, Karachi, Pakistan.

Correspondence: Dr. Muhammad Talat Mehmood, Professor Department of Paeds Surgery, Dow Medical College/Civil Hospital, Karachi, Pakistan.

E-mail: mtalatmehmood@yahoo.com

Received: March 03, 2009; accept: January 21, 2009

Multiple biopsies were taken from dilated as well as from normal sigmoid colon that came out to be normal. Post operative recovery was uneventful. Post operative ante-grade cystogram through vesicostomy showed narrow urethral opening into anterior rectal wall and left Vesico- uretric reflux (Figure II). Further management including gender reassignment was discussed with the parents. They did not turn up for follow up.

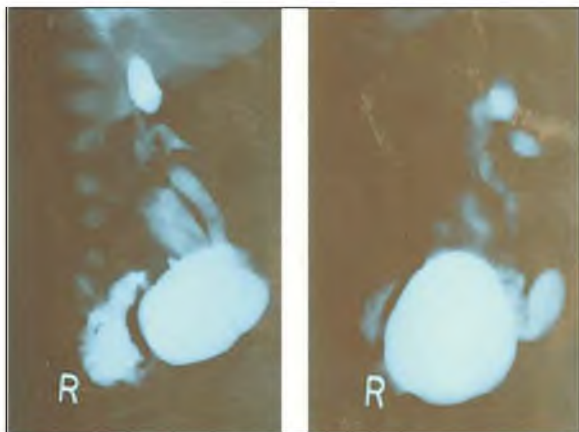


Figure 2: Antegrade cystogram through vesicostomy showing urethra pening into rectum & VUR in left sided duplex system.

DISCUSSION

Congenital segmental dilatation of the colon (SDC) is an extremely rare anomaly.¹ It is the presence of single, well defined segment of dilated intestine without any mechanical obstruction or anomaly of innervations with more or less abrupt transition to normal bowel proximally and distally.^{1,2} It can affect any part of the large bowel from caecum to rectum with the recto sigmoid being the commonest affected site.² In this patient mid sigmoid colon was involved. The fact that symptoms in all cases dates back to very early life, indicates congenital origin of the malformation.³ However the exact cause of SDC is unknown. Several theories have been proposed to explain its pathogenesis. Intra uterine vascular accident, congenital damage to the myenteric plexus, primary dysplasia, abnormal organogenesis, disturbance during splitting of the notochord from the endoderm have all been suggested as causative factors.^{2,3,5,6}

Most of the affected patients present beyond the

neonatal age with history of chronic constipation and abdominal distention that is commonly treated as functional constipation or confused with Hirschsprung's disease^{1,2,4}.

Only 11 cases have been reported in neonatal age and all presented as intestinal obstruction.³⁻¹³ Majority have associated anorectal malformations.^{6,7,10-13} The other congenital abnormalities associated with SDC include exstrophy of bladder,⁷ malrotation,^{4,13} short small intestine, dysmorphism,³ undescended testis,³ heteropic oesophageal mucosa,⁸ trisomy 21,⁴ Meckel's diverticulum and hydrops gallbladder,⁵ colonic atresia,^{8,11} myeloschisis and duplication of appendix.¹⁰ Definitive treatment of segmental dilatation of colon consists of segmental resection and primary anastomosis; however staged operations may be necessary if the patient's general condition is poor.

On the other hand congenital absence of the penis, or aphallia, is also a rare anomaly caused by developmental failure of the genital tubercle.¹⁴ The approximate incidence is 1 to 10 million populations.¹⁴ The phallus is completely absent, including the corpora cavernosa and corpus spongiosum. Usually, the scrotum is normal and the testes are descended. The urethra opens at any point in the perineum in midline from over the pubis to, most frequently, the anus or anterior wall of the rectum.¹⁶ Associated malformations are common and include cryptorchidism, renal agenesis, dysplasia or duplex system, vesicoureteral reflux, horseshoe kidney, anorectal malformations, musculoskeletal and cardiopulmonary abnormalities.¹⁶ This patient had left sided vesicoureteral reflux with duplex system.

Current recommendations are to reassign female gender to these patients by appropriate surgical and endocrine techniques.¹⁷ Infants with penile agenesis historically have undergone gender reassignment surgery, including bilateral orchidectomy with preservation of the scrotal skin for later vaginal reconstruction and urethral transposition,¹⁶ however, questions remain regarding in- utero gender imprinting and the long-term psychological effects of gender conversion. Considerable controversy surrounds the timing, role and the necessity of gender

reassignment.¹⁸ The long-accepted notion regarding the presence of a phallus or phenotypic phallic growth potential should not be the major criterion in recommending gender reassignment.

REFERENCES

1. Swenson O, Rathauser F. Segmental dilatation of the colon: A new entity. *Am J Surg* 1959; 97: 734- 8.
2. Al-Salem AH, Grant C. Segmental dilatation of colon: Report of a case and review of literature. *Dis Col Rect* 1990; 33: 515-8.
3. Helikson MA, Schapiro MB, Garfinkel DJ, Shermeta DW. Congenital segmental dilatation of the colon. *J Pediatr Surg* 1982; 17: 201-2.
4. Ngai RL, Chan AK, Lee JP, Mack CK. Segmental colonic dilatation in a neonate. *J Pediatr Surg* 1992; 27: 506-8.
5. Sarin YK, Singh VP. Congenital segmental dilatation of the colon. *Indian Pediatr* 1995; 32: 116-8.
6. Chadha R, Gupta S, Tanwar US, Mahazan JK. Congenital pouch colon associated with segmental dilatation of the colon. *J Pediatr Surg* 2001; 36:1593-5.
7. Aterman K, Abaci F. Heterotopic gastric and esophageal tissue in the colon. *Am J Dis Child* 1967; 113: 552-9.
8. Senocak ME, Bulut M. Caglar Mbuyukpamukcun. Congenital segmental dilatation of the colon with heterotopic esophageal mucosa. *Turk J Pediatr* 1987; 29:51-60.
9. Mathur P, Mogra N, Surana SS, Bordias. Congenital segmental dilatation of the colon with anorectal malformation. *J Pediatr Surg* 2004; 39: 18-20.
10. Rizalar R, Sarac A, Gork AS Somuneu S, Bernay F, Gurses N. Duplication of appendix with segmental dilatation of the colon, Myeloschisis and Anal atresia. *Eur J Pediatr Surg* 1996; 6: 112-3.
11. Kothari P, Gowrishankar, Rastogi A Depali R, Kulkarni B. Congenital segmental dilatation of colon with colonic atresia. *Ind J Gastroenterol* 2005; 24: 123-4.
12. Mahajan JK, Mohanan A, Rao K. Segmental dilatation of colon associated with anorectal malformation. *J Ind Assoc Pediatr Surg* 2009;12: 32-3.
13. el Shafie M. Congenital short intestine and cystic dilatation of the colon associated with ectopic anus. *J Pediatr Surg* 1971; 6: 70-6.
14. Elder JS. Congenital anomalies of the genitalia. In: Walsh PC, Retik AB, Vaughn ED, and Wein AJ. *Campbell's Urology* 8th eds. Philadelphia, Pa: WB Saunders; 2002: 2334-52.
15. Klein MD: Congenital abdominal wall defects. In: Ashcraft KW, *Pediatric surgery* 4th ed. Philadelphia, Pa: WB Saunders; 2006: 659-69.
16. Evans JA, Erdile LB, Greenberg CR, Chudley AE. Agenesis of the penis: patterns of associated malformations. *Am J Med Genet* 1999; 84: 47-55.
17. Gluer S, Fuchs J, Mildenerger M. Diagnosis and current management of penile agenesis. *J Pediatr Surg* 1998; 33: 628 – 31.
18. Bruch SW, Melvi M, Harrison MR. Immediate reconstruction of penile agenesis. *J Pediatr Surg* 1996; 31: 1152-4.

