

## CASE REPORT

# Prosthetic Rehabilitation of a Female Child with Ectodermal Dysplasia

Aleshba Saba Khan,<sup>1</sup> Abdul Mueed Zaigham,<sup>2</sup> Maryam Mumtaz<sup>2</sup>

1. Department of Prosthodontics, Shahida Islam Medical & Dental College Lodhran, Pakistan.

2. Department Institute of Dentistry, CMH Lahore Medical College, Lahore, Pakistan.

Correspondence to: Dr. Aleshba Saba Khan, Email: [aleshba.saba@hotmail.com](mailto:aleshba.saba@hotmail.com), ORCID: [0000-0002-2078-4266](https://orcid.org/0000-0002-2078-4266)

## ABSTRACT

Ectodermal Dysplasia (ED) is an X-linked inherited disorder with male predominance. Female patients may show partial expression of Ectodermal Dysplasia. Significant findings include hypodontia, hyposalivation, protuberant lips, conical teeth and loss of vertical dimension. The alveolar ridge fails to develop properly. Thus it presents as a challenge to dental treatment. This paper presents a case of prosthetic rehabilitation of an 8 years old girl having hypodontia associated with hypohidrotic ectodermal dysplasia with removable partial denture in maxilla after temporary fixed prosthesis and complete denture in mandible to rehabilitate the patient for esthetics and function.

**Keywords:** Ectodermal Dysplasia, Prosthetic Rehabilitation, Hypodontia.

This is an Open Access article distributed under the terms of the Creative Commons Attribution Non-Commercial License (<http://creativecommons.org/licenses/by-nc/4.0>) which permits unrestricted non-commercial use, distribution, and reproduction in any medium, provided the original work is properly cited.

## INTRODUCTION

Ectodermal dysplasia (ED) is an X-linked recessive gene hereditary disorder affecting 2 or more structures derived from ectodermal layer.<sup>1,2</sup> It is seen more commonly in males.<sup>1,2</sup> The prevalence in females is 1 in 100,000 cases.<sup>1,3</sup> Females may present with mild structural changes only due to partial expression of abnormal genes.<sup>1,2</sup> Clinically it can be classified into two major types depending on the functionality of the sweat glands: hypohidrotic- anhidrotic type and hidrotic type.<sup>1,4</sup>

Hypohidrotic- Anhidrotic type appears to be the most frequent type of ectodermal dysplasia where the sweat glands are either absent or markedly reduced in number and function, causing heat intolerance.<sup>5</sup> It is distinguished by the triad of hypotrichosis (skin, hair, and nail anomalies), hypodontia and hypohidrosis (partial or total absence of sweat glands); Hidrotic ectodermal dysplasia affects teeth, hairs, nails but unaffected sweat glands.<sup>1</sup>

Dental characteristics include anomalies such as anodontia or severe hypodontia (with or without a cleft lip and palate), lack of alveolar ridge development and xerostomia.<sup>3,5</sup> Edentulous appearance with tendency towards class III skeletal pattern; reduced lower face height; usually anomalies of tooth shape or microdontia (peg-shaped teeth in both dentitions, talons cusp,

taurodontia).<sup>3,5</sup> Partial or total anodontia results in some loss of function and esthetics.<sup>3,5</sup>

The objective of this article is to present a case of prosthetic rehabilitation of an 8 years old girl having hypodontia associated with hypohidrotic ectodermal dysplasia.

## CASE REPORT

An 8 years old girl, reported to the Prosthodontics department at Institute of Dentistry, CMH Lahore Medical College, with the complaint of inability to eat properly with existing dentures as well as unaesthetic upper anterior teeth.

Previous dentures (Fig. 1 A, B) were given at the age of 5 years that she used for 3 years despite the loss of retention and stability with time.

She was a diagnosed case of hypohidrotic ectodermal dysplasia at 1 year of age after long term pyrexia of unknown origin. During this one year, she was treated with vancomycin for fever that led to mild hearing loss for which she was given a cochlear implant. She was also consulting speech therapist at regular intervals for improvement in her speech.

On extra oral examination, distinct features of Ectodermal Dysplasia (E.D) i.e.; frontal bossing, saddle nose, thick and everted lips, angular cheilitis, scanty hairs and eye brows were seen. Conjunctokeratosis was

very mild and she did complain of nasal dryness.

Intra oral examination (Fig. 1 C, D) revealed presence of only 5 teeth; conical maxillary central incisors and canines and a molar in mandibular right quadrant. Excessive undercuts present in maxillary labial sulcus region due to proclined maxillary anterior teeth. No caries seen in any tooth but there was plaque accumulation and white curd like patches in maxillary labial sulcus and tongue were present. Ridges in both arches were underdeveloped and knife edge (class IV-Atwood's classification). Xerostomia resulted in mild ulceration/inflammation of underlying tissues in contact with existing dentures.

On examination of old dentures (Fig. 1:A, B), the dentures did not fit well on the ridges leads to loss of retention, stability and support. No clasps in the maxillary partial denture and mandibular complete denture having space for right mandibular molar. Adherent curd like patches on tissue surface of denture were seen. Fractured artificial canine and premolar on right side in mandibular denture.

Orthopantomograph (Fig. 2) revealed no un-erupted teeth, and thin bone remaining at the ridge.

**Treatment procedure:** Parents were explained about the treatment plan. Oral hygiene instructions were given along with oral nystatin-antifungal suspension (Nilstat drops) for management of oral candidiasis. Primary impression was made with alginate for diagnostic purposes.

Special trays fabricated with spacer and impression was made with addition silicone putty used for border molding to achieve border seal and light body material to achieve intimate contact with tissues and to impart minimal pressure. Minimal reduction of maxillary teeth present was done and two 3 unit fixed partial dentures made of composite resin (#13-11 and #21-23) were fabricated to restore esthetics and replace lateral incisors. To close the diastema, width of teeth was increased proportionately while fabrication (Fig. 3).

Impressions re-made after cementation of bridge. Conventional denture construction procedures were followed. Partial denture was fabricated for maxillary arch with C-shaped clasps made of 0.6mm stainless steel wire grasping maxillary canines (Fig. 1: E).

Mandibular denture was fabricated leaving behind the last molar tooth and not using any clasp on it due to small crown height.

Instructions of frequent sipping of water were given to manage xerostomia. Denture and oral hygiene instructions were reinforced as well as regular recalls every month then at 3 months and then as required were planned.

After a year, due to jaw growth and a subsequent increase in bite force, the patient reported with fracture of her mandibular denture in the midline and poor fit of the maxillary denture. On clinical examination, it was found that the patient had outgrown her dentures. Therefore new dentures were fabricated (Figs. 1: G, H).

It is necessary to evaluate and modify the dentures regularly or provision of new dentures to cater for normal growth and development of craniofacial structures, as well as managing any possible discomfort of the patient. Benefits of maxillo-facial surgery, fixed prosthesis and implant placement as a definitive, comfortable and aesthetic solution for patients with ectodermal dysplasia, could be taken into account once the skeletal growth is completed.

## DISCUSSION

Early treatment in Ectodermal Dysplasia improves appearance, functions and psychosocial well-being.<sup>5</sup> Removable prosthesis is the most commonly used treatment modality because it is conservative and cost effective.<sup>2,3,7</sup> Other modalities include implant supported dentures, over dentures and flexible dentures.<sup>8</sup>

Implant placement in anterior mandible is considered as effective treatment option that would preserve the bone as well as improve retention, support and stability of the prosthesis.<sup>9</sup> Implants were not considered in this case because of lack of sufficient bone and there is still potential for vertical growth in mandible that might result in change in angulation of implants.<sup>10</sup> This will impede availability of best treatment options once growth is complete and definitive treatment can be done. Also, the long term clinical evidence of implants in children with ectodermal dysplasia is still limited.<sup>10</sup>

Some articles have reported the management of the similar cases with removable partial dentures in children which is in accordance with this case report. The main reason for this is that removable denture can be modified easily to accommodate for the growth of the jaws apart from being cost effective and conservative treatment option.<sup>2,7,8,11</sup>

Few cases were managed with overdentures which is in contrast to the management of case in present article.<sup>12,13</sup> Overdentures are considered a suitable option when root formation is complete.<sup>13</sup> We did not opt for this option as it might require endodontic treatment because slight preparation of teeth should be done and young patients have large pulp chambers, root formation was not complete, also the patient was not very compliant. Overdentures should be

considered more when planning the definitive treatment.

Flexible dentures are another treatment modality that has been used for management of some cases but this specific case was not rehabilitated by flexible dentures to keep the cost of the treatment economical.<sup>8,13</sup>

Prosthetic rehabilitation includes various options like removable complete, partial or over dentures, fixed dental prosthesis, and/or provision of endosseous implants.<sup>2,5</sup> Patient's age, clinical features as well as economic status of the patient are the major determinants for selection of treatment option.

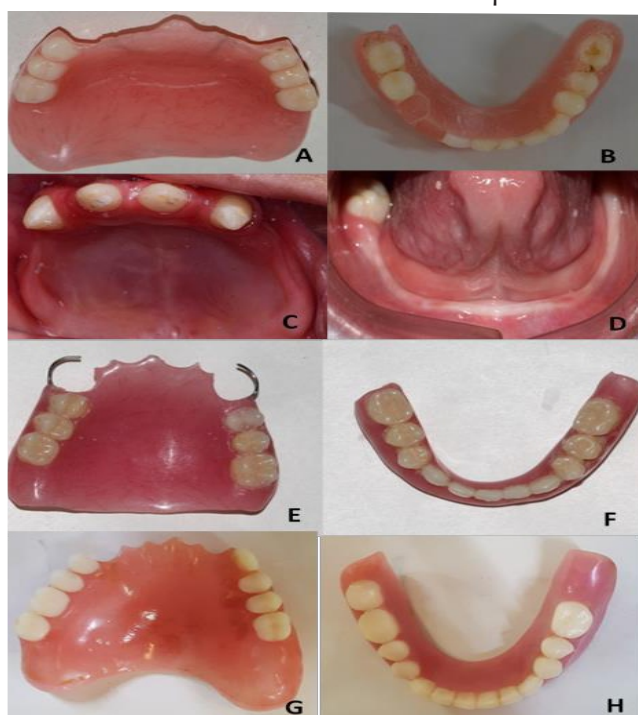


Figure 1 A-H: A,B 3 years old dentures, C,D intraoral pictures, E,F New Dentures, G,H 1 year post insertion of Denture in E,F)

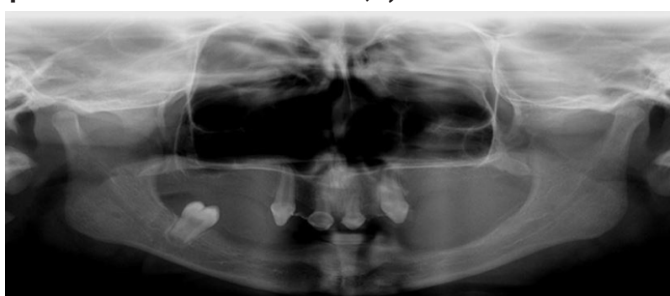

Figure 2: Orthopantomogram of the patient at age of 8 years

## CONCLUSION

The child was successfully rehabilitated in terms of function and esthetics. She was able to eat the food with soft and medium consistency and was happy with her esthetics. The compliance improved in terms of managing oral hygiene, hygiene of dentures and

regular dental visits for follow ups.

Patients with ectodermal dysplasia require a multidisciplinary strategy for treatment planning and dental treatment to restore social well-being, esthetics and function. Only Prosthetic support was used in this case since it did not require help of any other dental specialty at the moment. Provision of removable dentures is a rational, feasible and economic option at this age of the patient.

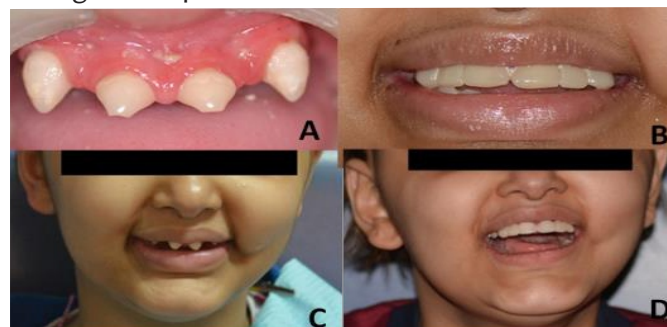

Figure 3: Pre insertion and post insertion pictures

## CASE REPORT

- Garcia-Martin P, Hernandez-Martin A, Torrelo A. Ectodermal dysplasias: a clinical and molecular review. *Actas Dermosifiliogr* 2013; 104:451-70. [doi: 10.1016/j.ad.2012.07.012](https://doi.org/10.1016/j.ad.2012.07.012).
- Bidaki M, Moghadam NC, Takhtdar M, Kamareh S, Kordafshari B. Complete denture prosthodontics in children with ectodermal dysplasia: systematic review from case reports and case series reports. *J Int Pharm Res* 2019; 46:181-4.
- Gurcan AT, Koruyucu M, Seymen F, Yardımcı S. Case series of ectodermal dysplasia and evaluation of oral findings: A literature review. *Ann Med Res* 2020; 27:420-5.
- Chandrapoja J, Ganapathy DD. Evaluation of knowledge and attitude regarding the prosthetic management of ectodermal dysplasia patients among the post graduate students in Chennai. *IJSDR* 2021; 6:293-9.
- Arya V, Yadav B, Bhargava A, Sheorain A, Sehgal M. Prosthetic management of ectodermal dysplasia patient with dental implants : A case report. *J Dent College Azamgarh* 2021; 17:63-72.
- Pinto AS, Conceição Pinto ME, Melo do Val C, Costa Oliveira L, Costa de Aquino C, Vasconcelos DF. Prosthetic management of a child with hypohidrotic ectodermal dysplasia: 6-year follow-up. *Case Rep Dent* 2016; 2016:2164340. [doi: 10.1155/2016/2164340](https://doi.org/10.1155/2016/2164340).
- Schnabl D, Grunert I, Schmuth M, Kapferer-Seebacher I. Prosthetic rehabilitation of patients with hypohidrotic ectodermal dysplasia: A systematic review. *J Oral Rehabil* 2018; 45:555-70. [doi.org/10.1111/joor.12638](https://doi.org/10.1111/joor.12638).

8. Sfeir E, Nassif N, Moukarzel C. Use of mini dental implants in ectodermal dysplasia children: follow-up of three cases. *Eur J Paediatr Dent* 2014; 15:207-12.
9. AlNuaimi R, Mansoor M. Prosthetic rehabilitation with fixed prosthesis of a 5-year-old child with Hypohidrotic Ectodermal Dysplasia and Oligodontia: a case report. *J Med Case Rep* 2019; 13:329. [doi: 10.1186/s13256-019-2268-4](https://doi.org/10.1186/s13256-019-2268-4).
10. Mittal M, Srivastava D, Kumar A, Sharma P. Dental management of hypohidrotic ectodermal dysplasia: A report of two cases. *Contemp Clin Dent* 2015; 6:414-7. [doi:10.4103/0976-237X.161907](https://doi.org/10.4103/0976-237X.161907).
11. Maroulakos G, Artopoulou II, Angelopoulou MV, Emmanouil D. Removable partial dentures vs overdentures in children with ectodermal dysplasia: two case reports. *Eur Arch Paediatr Dent* 2016; 17:205-10. [doi:10.1007/s40368-015-0212-x](https://doi.org/10.1007/s40368-015-0212-x).
12. Gupta C, Verma M, Gupta R, Gill S. Telescopic overdenture for oral rehabilitation of ectodermal dysplasia patient. *Contemp Clin Dent* 2015; 6:S258-61. [doi: 10.4103/0976-237X.166821](https://doi.org/10.4103/0976-237X.166821).
13. El Mekawy N, Ibrahim CR, Hegzy S. Tooth Overdentures Denture Base Materials. *Highlights on Medicine and Medical Research* 2021; 9:76-96. [doi.org/10.9734/bpi/hmmr/v9/2047F](https://doi.org/10.9734/bpi/hmmr/v9/2047F).

