

ORIGINAL ARTICLE

## Comparison of Symphysis Morphology in Normodivergent Patients of the Short and Normal Mandible

Erum Behroz Khan, Hunny Kumari, Ayesha Bibi, Danish Mottani, Sarvaich Kumar

Orthodontics Department, Sindh Institute of Oral Health Science, Jinnah Sindh Medical University Karachi, Pakistan.

Correspondence to: Dr. Erum Behroz Khan, Email: [erumbehroz@gmail.com](mailto:erumbehroz@gmail.com), ORCID: [0000-0002-6192-5440](https://orcid.org/0000-0002-6192-5440)

### ABSTRACT

**Objective:** To compare the morphology of symphysis in normodivergent patients of short and normal mandible attending outpatient department of large public sector dental hospital of Karachi, Pakistan.

**Methods:** This was a prospective observational study that was carried out at the outpatient department of the orthodontics, Sindh Institute of Oral Health Sciences, from June-2020 to December-2020. The study included 70 (35 in each group) patients with a normal angle MMA over the range of  $25.5^{\circ} \pm 5.3^{\circ}$ . McNamara analysis has been carried out including all the patients and dividing into two groups i.e., normal mandible and short mandible. On cephalogram, perpendicular distance from Pog to B-Me line, angle symphysis vertical dimension (B-B1-Gn), and angle symphysis convexity (B-Pog-Me), were measured for all patients.

**Results:** Out of seventy (70) patients, there were 24 (34.3%) males and 46 (65.7) females. Patients were equally divided into two groups, i.e., short 35 (50.0%) and normal mandible 35 (50.0%). The mean angle of symphysis convexity, symphysis vertical dimension, and anterior prominence of symphysis of participants were  $124.6 \pm 42.8$ ,  $49.9 \pm 4.7$ , and  $4.1 \pm 1.1$  respectively. Patients with short mandible were found to have significantly higher in symphysis convexity as compared to patients of normal mandibular, i.e.,  $136.54 \pm 3.55$  and  $112.74 \pm 58.53$  respectively, (p-value= 0.022).

**Conclusion:** Symphysis convexity was found greater in short mandible patients showing that in short mandible patients, symphysis was flatter anteriorly, less convex, and less prominent.

**Keywords:** Morphology, Mandible, Orthodontics, Symphysis.

This is an Open Access article distributed under the terms of the Creative Commons Attribution Non-Commercial License (<http://creativecommons.org/licenses/by-nc/4.0>) which permits unrestricted non-commercial use, distribution, and reproduction in any medium, provided the original work is properly cited.

### INTRODUCTION

Mandibular Symphysis (MS) is referred to as the infusion line found at the lateral halves of the mandible.<sup>1</sup> It acts as one of the sources for the grafting of the bones (remodeling). It was noticed that the structure of MS influenced the diagnosis and treatment planning for orthodontic patients. The previous study also showed that MS plays an important role in enhancing the beauty of the face particularly in the lower region of the jaw.<sup>1,2</sup> The predictor for the direction of mandible growth rotation is MS.<sup>3</sup> It was also found that in the initial developmental phases, there is the role of MS in developing the components such as symphyseal and condylar components. The associated structure can be influenced such as the morphology of the growth plate along with the bone formation of endochondral parts. Orthodontic patients have an increased risk of developing gingival recession.<sup>4,5</sup> The symphysis is a development zone, prominent in both the length and width of the mandibular development within the first

half of the prenatal period. Mandible symphysis is one of the regions that is usually changed according to the types of face form and its associated patterns. The mandibular symphysis represents the third jaw joint of the mammalian masticatory system.<sup>6</sup> Moreover, the sagittal, as well as vertical positions of mandibular incisors, are observed to be significant indicators in the structuring of skeletal and occlusal regions for the treatment along with surgical processes. Thus, the structuring of alveolar bone is considered to be playing a key role in differential diagnosis. During orthodontic treatment limited movement of incisors generally depends on the structure of alveolar bone.<sup>7</sup> Several pieces of research had been conducted regarding differences in craniofacial variables concerning such as anteroposterior dimension, deep bite, crowding and inclination of the lower incisor, and their relation with MS.<sup>8</sup> Hence, the purpose of this study was to evaluate the mean symphysis morphology in patients undergoing orthodontic treatment and compare the properties of

the symphysis morphology in patients with small mandibles and normal mandibles. Despite the research studies carried out in the past on this aspect, there is still limited knowledge and information. By taking into account the larger sample size as the sample size in the previous studies was small to reach over on the conclusive outcomes.

## METHODS

This prospective observational study was carried at the outpatient department of the Orthodontics, Sindh Institute of Oral Health Science, Jinnah Sindh Medical University Karachi, Pakistan from June to December 2020. Ethical approval has been taken by the institutional review board under approval number JSMU/IRB/2020/-386. Non-probability consecutive sampling technique was used to enroll study participants. Informed written consent was taken and clinical examination was done by the principal investigator.

By using an open EPI sample size calculator taking mean  $\pm$  SD of low and normal angle i.e  $4.6 \pm 0.82$ ,  $5.25 \pm 1.21$ , level of confidence 95% power of test 80%. The estimated sample size was 35 per group.<sup>9</sup> The inclusion criteria were both male and female patients of CVM stage 5, the age range of 16 to 18 years, patients with a normal angle MMA over the range of  $25.5^\circ \pm 5.3^\circ$  and patients with complain of malaligned teeth who were undergoing orthodontic treatment. Patients with a history of any surgical treatment, any syndrome as well as cleft lip and palate have been excluded from the study. A lateral cephalometric radiograph was done for each patient by the radiologist. All subjects were positioned in the cephalogram with the sagittal plane at a right angle to the path of X-rays, the Frankfort plane parallels to the horizontal, the teeth in centric occlusion, and the lips slightly closed. Radiographs were hand-traced upon paper with a lead pencil over a well-illuminated viewing screen. The linear measurement with a measuring scale and the angular measurements with a protractor were measured by the same investigator. McNamara analysis has been carried out including all the patients and dividing them into two groups, i.e., short and normal mandible. In this analysis, the difference between the effective maxillary and mandible lengths was also evaluated. The patients were divided based on the difference between effective maxillary and mandible lengths.

Point B is defined as the most posterior point on the mandible profile among the alveolar crest and chin points. Pogonion (Pog) is defined as the most anterior

point on the contour of the chin. Moreover, Gnathion (Gn) is the midpoint of the counter connecting the ramus and body of the mandible.<sup>7</sup> However, mid-facial length is determined by measuring a line from condylion (Co) the posterosuperior point on the outline of mandibular condyle to point A. The Mandibular length is the measured distance from condylion (Co) to point Gnathion (Gn).<sup>8</sup> Moreover, the normal mandibular length is the linear maxillo mandible difference (mid-facial length- mandible length) should be between 27 to 30 and the small mandible is described as the linear maxillo mandible difference (mid-facial length - mandible length) is less than 27 to 30mm. (Figure-1)

Point B1 is defined as a point created by the junction of a perpendicular line dropped from point B to the tangent drawn on the internal contour of the mandibular symphysis at a short distance from point B. Moreover, the B-B1-Gn angle is the angle between point B, point B1, and Gn; gives an indirect reflection of the vertical dimension of the mandibular symphysis and B-Pog-Me is the angle formed between point B, Pog, and Me, it reflects the convexity of mandible symphysis. The perpendicular distance from the pogonion to the B-Me line is the perpendicular distance from point Pog to the line connecting point B and Me represents the anterior prominence of mandibular symphysis.<sup>10</sup> (Figure-2)

The mean position between both images of the anatomical bony structures was observed to determine the cephalometric points. Furthermore, effective mandibular length, MMA angle, and effective maxillary length were computed on the cephalogram. Angle B-B1-Gn, angle B-Pog-Me, and perpendicular distance from pog to B-Me were measured on a cephalogram. (Figure-2) Data entry and analysis were done using a statistical package for social sciences (SPSS) version 20.0. Frequencies and percentages were calculated for gender and mandibular length. The quantitative variables like symphysis convexity, symphysis vertical dimension, and anterior prominence of symphysis were measured as mean  $\pm$  SD. Inferential statistics were explored using an Independent t-test. The p-value of  $\leq 0.05$  was considered statistically significant.

## RESULTS

Of the total 70 patients, there were 24 (34.3%) males and 46 (65.7) females. patients were divided into two groups, i.e., short 35 (50.0%) and normal mandible 35 (50.0%). The mean angle of symphysis convexity, symphysis vertical dimension, and anterior prominence of symphysis of participants were  $124.6 \pm 42.8$ ,  $49.9 \pm$

4.7, and  $4.1 \pm 1.1$  respectively.

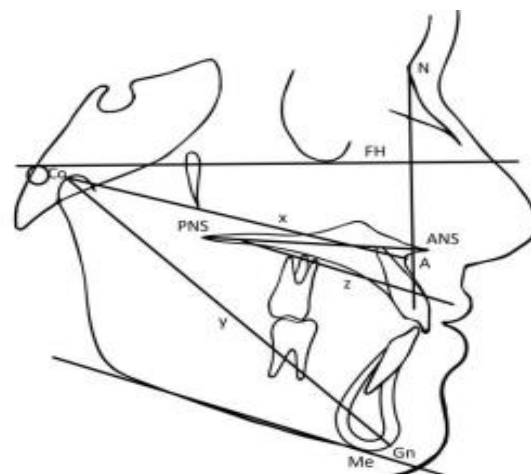
Patients of short mandibular were found significantly higher in symphysis convexity as compared to patients of normal mandibular, i.e.,  $136.54 \pm 3.55$  and  $112.74 \pm 58.53$  respectively, (p-value= 0.022). While the mean difference of short mandibular was lower as compared to normal mandibular in symphysis vertical dimension ( $49.82 \pm 3.93$ ) vs. ( $49.97 \pm 5.45$ ) and anterior prominence of symphysis ( $4.14 \pm 1.11$ ) vs. ( $4.28 \pm 0.92$ ). An insignificant mean difference of symphysis vertical dimension (p-value 0.901) and anterior prominence of symphysis (p-value 0.436) was observed in study groups. (Table 1)

Mandibular length of female patients was found significantly higher in symphysis vertical dimension as compared to male patients, i.e.,  $50.78 \pm 3.52$  and  $48.20 \pm 6.17$  respectively, (p-value= 0.029). An insignificant mean difference of symphysis convexity (p-value 0.691) and anterior prominence of symphysis (p-value 0.553) was observed in male and female patients. (Table 2)

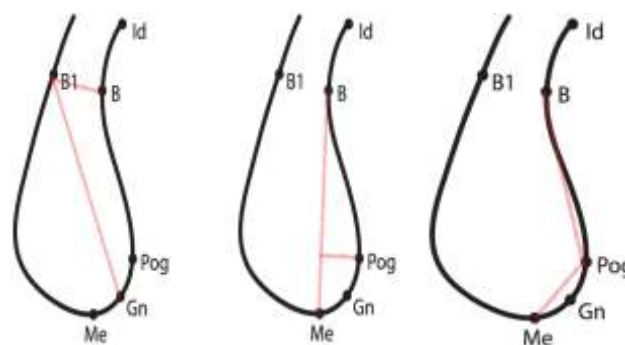
Among patients with short mandible, symphysis convexity was found insignificantly higher in male patients  $136.7 \pm 4.42$  as compared to female patients  $136.4 \pm 3.17$ , (p-value 0.839). Similarly, symphysis vertical dimension (p-value 0.230) and anterior prominence of symphysis (p-value 0.530) were also found to be insignificant. While patients with normal mandible, symphysis convexity was found insignificantly higher in female patients  $114.8 \pm 52.74$  as compared to male patients  $109.1 \pm 69.40$ , (p-value 0.785). Similarly, symphysis vertical dimension (p-value 0.076) and anterior prominence of symphysis (p-value 0.891) were also found to be insignificant. (Table 3)

## DISCUSSION

In the current study, it is shown that the mean symphysis convexity of the short mandibular patients was higher than the normal mandibular patients. Multiple studies have been carried out on symphysis morphology but the study regarding the normodivergent patients of the short and normal mandible is lacking among patients undergoing orthodontic treatment in our population. Therefore, we have done this study to identify alveolar compensation between the short and normal mandible. Because Patients with short mandible have alveolar compensation, which included reversed upper incisor and a proclined lower incisor. A common clinical finding within our population is that the chin of the shorter jaw is more prominent and in the patients with narrow mandible symphysis, therefore, during the



**Figure 1:** x is the effective Maxillary length; y is the effective Mandibular length and z is MMA



**Figure 2:** Angle symphysis vertical dimension (B-B1-Gn), the perpendicular distance from Pog to B-Me line, and angle symphysis convexity (B-Pog-Me)

procedure of orthodontic treatment tooth movement should be carefully performed.<sup>11</sup>

The following findings of our study obtained measurements were always higher among males than in females. In normal mandibular patients, the mean vertical dimension of the symphysis is longer than in short mandibular patients. However, this difference was statistically insignificant. In the previous study, Linjawi et al observed males had significantly greater MS surface area, dentoalveolar length, skeletal symphysis length, total symphysis length, vertical symphysis dimension, and symphysis convexity.<sup>12</sup> It was also found that among the patients having a normal angle, the research further did not carry out regarding the morphology of symphysis.<sup>13</sup> Pintavirooj et al and Uzuner et al found that decrease width of the alveolar symphysis and increased height of MS may relate to hyperactivity of mentalis muscle, deep bite.<sup>14-15</sup> Class-III subjects showed less anterior concavity of the MS and greater inclinations of the alveolar part of the MS than did class-I and class-II malocclusion and

**Table 1: Mean differences of mandibular symphysis measured parameters according to short and normal mandibles (n=70)**

| Variables                        | Mandibular Length |                   | p-value | 95% Confidence Interval |       |
|----------------------------------|-------------------|-------------------|---------|-------------------------|-------|
|                                  | Short<br>(n= 35)  | Normal<br>(n= 35) |         | Upper                   | Lower |
| Symphysis Convexity              | 136.54 ± 3.55     | 112.74 ± 58.53    | 0.022*  | 43.93                   | 3.66  |
| Symphysis Vertical Dimension     | 49.82 ± 3.93      | 49.97 ± 5.45      | 0.900   | 2.12                    | -2.41 |
| Anterior Prominence of Symphysis | 4.14 ± 1.11       | 4.28 ± 0.92       | 0.436   | -0.63                   | 0.34  |

Independent t-test applied, \*p-value ≤0.05 considered as significant

**Table 2: Mean differences of mandibular symphysis measured parameters according to gender (n=70)**

| Variables                        | Gender          |                   | p-value | 95% Confidence Interval |       |
|----------------------------------|-----------------|-------------------|---------|-------------------------|-------|
|                                  | Male<br>(n= 24) | Female<br>(n= 46) |         | Upper                   | Lower |
| Symphysis Convexity              | 121.79 ± 52.14  | 126.13 ± 37.71    | 0.691   | -26.01                  | 17.33 |
| Symphysis Vertical Dimension     | 48.20 ± 6.17    | 50.78 ± 3.52      | 0.029*  | -4.88                   | -0.27 |
| Anterior Prominence of Symphysis | 4.20 ± 1.02     | 4.04 ± 1.09       | 0.553   | -0.37                   | 0.69  |

Independent t-test applied, \*p-value ≤0.05 considered as significant

**Table 3: Mean differences of mandibular symphysis measured parameters according to gender among patients of short and normal mandibles (n=70)**

| Mandibular Length                | Parameters                       | Gender      | Mean ± SD     | p- value | 95% Confidence Interval |       |
|----------------------------------|----------------------------------|-------------|---------------|----------|-------------------------|-------|
|                                  |                                  |             |               |          | Upper                   | Lower |
| Short                            | Symphysis Convexity              | Male        | 136.7 ± 4.42  | 0.839    | -2.39                   | 2.93  |
|                                  |                                  | Female      | 136.4 ± 3.17  |          |                         |       |
|                                  | Symphysis Vertical Dimension     | Male        | 48.6 ± 4.67   | 0.230    | -4.63                   | 1.15  |
|                                  |                                  | Female      | 50.3 ± 3.52   |          |                         |       |
| Normal                           | Anterior Prominence of Symphysis | Male        | 4.1 ± 0.98    | 0.530    | -0.58                   | 1.11  |
|                                  |                                  | Female      | 3.9 ± 1.21    |          |                         |       |
|                                  | Symphysis Convexity              | Male        | 109.1 ± 69.40 | 0.785    | -47.94                  | 36.53 |
|                                  |                                  | Female      | 114.8 ± 52.74 |          |                         |       |
| Symphysis Vertical Dimension     | Male                             | 47.8 ± 7.38 | 0.076         | -7.13    | 0.37                    |       |
|                                  | Female                           | 51.2 ± 3.54 |               |          |                         |       |
| Anterior Prominence of Symphysis | Male                             | 4.2 ± 1.09  | 0.891         | -0.66    | 0.76                    |       |
|                                  | Female                           | 4.1 ± 0.95  |               |          |                         |       |

Independent t-test applied, \*p-value ≤0.05 considered as significant

direction of mandible.<sup>10,16</sup> In contrast, Mangla et al, observed that symphysis had a low height, a wide width, a limited ratio (height/width), and a greater angle of the symphysis in the hypo-divergent facial form, and for hyper divergent facial types it was reversed and along with the genetic research studies, particularly in the Pakistan region.<sup>17</sup>

As per the current study findings, anterior prominence of symphysis the mean invasion of patients with a short mandible was less than that of a normal mandible, but

this difference was not statistically significant, this result indicates less prominence of the chin in patients of the short mandible. Increasing the size of the mandible increase the prominence of the chin.<sup>18</sup> In the previous study of Syed et al these finding was also similar but has the value of significance.<sup>9</sup> It has been noted in the research of Tang et al that the effect of an abnormal vertical skeletal pattern on morphological features of MS is greater than that of an abnormal sagittal skeletal pattern.<sup>19</sup> Therefore, only patients at a

normal angle were included in the current study to exclude the effects of high or low positions of MS, and this study concentrates on effective maxillary and mandibular lengths. Other than this another study, by Ahn MS *et al* showed that the wider width of the symphysis provides a greater incisor movement and a greater opportunity for treatment with non-extraction patterns.<sup>11</sup> In contrast, Jain S *et al* mentioned in their study that people with a small chin and greater symphysis height were suitable for an extraction treatment plan to compensate for the difference in dental arch length.<sup>20</sup> The factors of symphysis that as height and width affect the treatment plan.

It should be remembered that the symphysis area restricts not only the sagittal movement for reconstructing evolutionary relationships of primates, and finds potential evidence for the independent evolution of symphyseal fusion within the crown anthropoid clade. but also the vertical movement of the teeth and lower incisor angulation and actual symphysis have a strong positive correlation.<sup>21</sup>

According to a finding in this study, short mandible patients' symphysis convexity was more than in normal mandible patients. This value is statistically significant in our study. Previous studies of Syed *et al* had similar results.<sup>9</sup> This value indicates that symphysis is relatively flat in patients with a short mandible. In our medical institution, in patients with a short mandible, the area of access to the jaw may depend on the horizontal and vertical growth pattern and genetic control, rather than compensation for the mandible. Alveolar bone compensation is often a good indication of potential anteroposterior (AP) differences. Changes in the orientation of the lower incisors to compensate for skeletal differences in different AP ratios can cause the MS surface to reshape and thus affect its contour. Although there are few clinical differences in the morphology of symphysis between patients with short and normal jaws, they are still very important to an orthodontist. They can be used in conjunction with other cephalometric measurements to determine general patterns of bone (skeletal) relationships. Besides, they can help us decide on a treatment plan either extraction or non-extraction. These findings reflect the importance of a holistic analysis of each patient in planning diagnosis and treatment.<sup>21</sup>

The limitation of this study includes a small sample size, due to being limited to one healthcare center, which undermined the generalization of the findings. Also, certain ethnic differences influence care choices in the standards of diagnostic criteria and morphological characteristics. Hence, the authors propose that a

sample be recruited from many institutes and have a large sample size to make future research more predictable and generalized outcomes.

## CONCLUSION

The morphology of short mandible patients is distinct from that of normal mandibular patients. From the study findings, it has been concluded that in short mandible patient's symphysis convexity was found to be greater and symphysis is flatter anteriorly, less convex, and less prominent.

**Acknowledgement:** The authors would like to acknowledge the staff in the orthodontic department for their kind assistance in providing materials and facilities for this study.

**ETHICAL APPROVAL:** This study was approved by Institutional Review Board, Jinnah Sindh Medical University Karachi, Pakistan (JSMU/IRB/2020/-386).

**AUTHORS' CONTRIBUTION:** EBK: Concept of the work. HK: Data collection, data analysis, interpretation. AB: Revision the manuscript. DM: Interpretation of data. SK: Drafting the manuscript.

**CONFLICT OF INTEREST:** The authors declare no conflict of interest.

**FUNDING:** None.

Received: February 04, 2021

Accepted: April 05, 2021

## REFERENCES

1. Sendyk M, Cevidanes LH, de Oliveira Ruellas AC, Fattori L, Mendes FM, de Paiva JB, et al. Three-dimensional evaluation of dental decompensation and mandibular symphysis remodeling on the orthodontic-surgical treatment of Class III malocclusion. *Am J Orthod Dentofacial Orthop* 2021; 159:175-83.e3. [doi:10.1016/j.ajodo.2019.12.020](https://doi.org/10.1016/j.ajodo.2019.12.020)
2. Hoenig JF. Sliding osteotomy genioplasty for facial aesthetic balance: 10 years of experience. *Aesthetic Plast Surg* 2007; 31:384-91. [doi:10.1007/s00266-006-0177-6](https://doi.org/10.1007/s00266-006-0177-6)
3. Gupta S, Dhingra PS, Chatha S. A study of comparison and correlation between antegonial notch depth, symphysis morphology, and ramus morphology among different growth patterns in angle's Class II Division 1 Malocclusion. *Indian J Dent Sci* 2018; 10:21. [doi:10.4103/IJDS.IJDS\\_109\\_17](https://doi.org/10.4103/IJDS.IJDS_109_17)
4. Slutzkey S, Levin L. Gingival recession in young adults: occurrence, severity, and relationship to past orthodontic treatment and oral piercing. *Am J Orthod Dentofacial Orthop* 2008; 134:652-6. [doi.org/10.1016/j.ajodo.2007.02.054](https://doi.org/10.1016/j.ajodo.2007.02.054)

5. Sugito H, Shibukawa Y, Kinumatsu T, Yasuda T, Nagayama M, Yamada S, et al. Ihh signaling regulates mandibular symphysis development and growth. *J Dent Res* 2011; 90:625-31. [doi.org/10.1177/0022034510397836](https://doi.org/10.1177/0022034510397836)
6. Ravosa MJ, Vinyard CJ. Masticatory loading and ossification of the mandibular symphysis during anthropoid origins. *Sci Rep* 2020; 10:1-9. [doi.org/10.1038/s41598-020-62025-8](https://doi.org/10.1038/s41598-020-62025-8)
7. Yamada C, Kitai N, Kakimoto N, Murakami S, Furukawa S, Takada K. Spatial relationships between the mandibular central incisor and associated alveolar bone in adults with mandibular prognathism. *Angle Orthod* 2007; 77:766-72. [doi.org/10.2319/072906-309](https://doi.org/10.2319/072906-309)
8. Esenlik E, Sabuncuoglu FA. Alveolar and symphysis regions of patients with skeletal class II division 1 anomalies with different vertical growth patterns. *Eur J Dent* 2012; 6:123-32.
9. Syed ST, Mahmood A, Nazir R. Comparison of symphysis morphology in normodivergent patients of the short and normal mandible. *Pak Orthod J* 2017; 9:87-92.
10. Shioya S, Arai K. Dentoskeletal morphology of adult Class II division 1 and 2 severe deep overbite malocclusions. *Orthod Waves* 2017; 76:97-104. [doi.org/10.1016/j.odw.2017.01.003](https://doi.org/10.1016/j.odw.2017.01.003)
11. Ahn MS, Shin SM, Yamaguchi T, Maki K, Wu TJ, Ko CC, et al. Relationship between the maxillofacial skeletal pattern and the morphology of the mandibular symphysis: Structural equation modeling. *Korean J Orthod* 2019; 49:170-80. [doi.org/10.4041/kjod.2019.49.3.170](https://doi.org/10.4041/kjod.2019.49.3.170)
12. Linjawi AI, Affy AR, Baeshen HA, Birkhed D, Zawawi KH. Mandibular symphysis dimensions in different sagittal and vertical skeletal relationships. *Saudi J Biol Sci* 2021; 28:280-5. [doi.org/10.1016/j.sjbs.2020.09.062](https://doi.org/10.1016/j.sjbs.2020.09.062)
13. Janson G, Goizueta OEFM, Garib DG, Janson M. Relationship between maxillary and mandibular base lengths and dental crowding in patients with complete Class II malocclusions. *Angle Orthod* 2011; 81:217-21. [doi.org/10.2319/062110-338.1](https://doi.org/10.2319/062110-338.1)
14. Pintavirooj P, Sumetcherngpraty R, Chaiwat A, Changsiripun C. Relationship between mentalis muscle hyperactivity and mandibular symphysis morphology in skeletal Class I and II patients. *Orthod Waves* 2014; 73:130-5. [doi.org/10.1016/j.odw.2014.09.006](https://doi.org/10.1016/j.odw.2014.09.006)
15. Uzuner FD, Aslan BI, Dinçer M. Dentoskeletal morphology in adults with Class I, Class II Division 1, or Class II Division 2 malocclusion with an increased overbite. *Am J Orthod Dentofacial Orthop* 2019; 156:248-56. e2. [doi.org/10.1016/j.ajodo.2019.03.006](https://doi.org/10.1016/j.ajodo.2019.03.006)
16. Chung CJ, Jung S, Baik H-S. Morphological characteristics of the symphyseal region in adult skeletal Class III crossbite and open bite malocclusions. *Angle Orthod* 2008; 78:38-43. [doi.org/10.2319/101606-427.1](https://doi.org/10.2319/101606-427.1)
17. Mangla R, Singh N, Dua V, Padmanabhan P, Khanna M. Evaluation of mandibular morphology in different facial types. *Contemp Clin Dent* 2011; 2:200-6. [doi: 10.4103/0976-237X.86458](https://doi.org/10.4103/0976-237X.86458)
18. Al-Khateeb SN, Al Maaitah EF, Abu Alhaija ES, Badran SA. Mandibular symphysis morphology and dimensions in different anteroposterior jaw relationships. *Angle Orthod* 2014; 84:304-9. [doi.org/10.2319/030513-185.1](https://doi.org/10.2319/030513-185.1)
19. Tang N, Zhao Z, Liao C, Zhao M. Morphological characteristics of mandibular symphysis in adult skeletal class II and class III malocclusions with abnormal vertical skeletal patterns. *Hua xi kou Qiang Yi Xue za zhi* 2010; 28:395-8.
20. Jain S, Puniyani P, Saifee A. Mandibular symphysis morphology and lower incisor angulation in different anteroposterior jaw relationships and skeletal growth patterns—a cephalometric study. *Med Pharm Rep* 2020; 93:97-104. [doi.org/10.1016/S0889-5406\(05\)81008-X](https://doi.org/10.1016/S0889-5406(05)81008-X)
21. Knigge RP, Vinyard CJ, McNulty KP. Mandibular symphyseal fusion in fossil primates: Insights from correlated patterns of jaw shape and masticatory function in living primates. *Am J Phys Anthropol* 2020; 173:322-36. [doi.org/10.1002/ajpa.24048](https://doi.org/10.1002/ajpa.24048)

